

THE RELATIONSHIP BETWEEN MYOCARDIAL BRIDGE TYPE AND PROXIMAL STENOSIS IN HYPERTENSIVE PATIENTS

Gouse Mohimuddin,¹ Xindao Yin,¹ Hui Xu,¹ Guanghui Xie,¹ Wenzhen Zhou,¹ Xinying Wu,¹ Qingqing Xu,¹ Mohammed Masood Mohiuddin,² Jiqiang Yue³

¹ Department of Radiology, Nanjing First Hospital, Nanjing, Jiangsu, P.R. China.

² Mahadevappa Rampure Medical College, Gulbarga, Karnataka, India.

³ Department of statistics, Nanjing Medical University, Nanjing, Jiangsu, P.R. China

PJR January - March 2013; 23(1): 16-21

ABSTRACT

BACKGROUND: Myocardial bridges (MB) are a congenital abnormality in which a part of the coronary artery is tunneled or immersed in the myocardium, most commonly found in the left descending artery (LAD). In the artery proximal to the bridge, there is formation of atherosclerosis. However the tunneled artery and proximal part of the artery is free from atherosclerosis. This study will investigate the relationship between myocardial bridges and proximal stenosis in hypertensive patients. **METHODS AND MATERIALS:** 140 myocardial patients were randomly selected from Nanjing's First Hospital's database, all aged between 31 and 91 years. 33 were further excluded from the study. The data of the remaining 107 patients, including the type of bridge, length, depth, BP, cholesterol level and artery involved, was all taken. The Pearson Chi square test was done to compare the relationship between the bridge type and degree of stenosis in the artery proximal to the bridge in hypertensive patients. **RESULTS:** Among those 107 patients, 69 (64.4%) had a superficial bridge and 38 (35.5%) had a deep bridge. The p value of the superficial bridge group was (0.993) while that of the deep bridge group was (0.580). **CONCLUSION:** In this study superficial bridges were the most common form of myocardial bridge, and the most common artery involved was the (middle segment of) LAD. There were no signs of atherosclerosis in the MB (or tunneled) arteries or the distal parts. This study found no link between myocardial bridges and proximal stenosis in hypertensive patients.

Keywords: Myocardial bridge; stenosis; hypertension; superficial bridge; deep bridge; stage 1; stage 2

Introduction

The myocardial bridge (MB) is an anatomical variant in which part of the coronary artery runs under the myocardium.¹ MB was first seen by Reyman during an autopsy in 1737² and in 1960 it was angiographically observed for the first time by Portmann and Iwig.³ It is also called tunnel artery.⁴ It mostly occurs in the left ascending artery (LAD). The affected artery may have two bridges. In MB depth and length varies from 1-4 mm and 4-40 mm respectively. The detection rate of MB is higher in

multi-detector tomography (MDCT) than coronary angiography (CAG). The detection rate of MB in autopsy is between 57 and 80%.

MB can be divided into following two types: superficial and deep. In a superficial bridge the artery is covered by the membranous myocardium, while in deep bridges the artery in the myocardium shows a 'U' shape.

During the systolic phase the artery beneath the bridge is compressed by the surrounding myocardium, leading to transient stenosis in the artery seen particularly in deep bridges, which relaxes

Correspondence : Dr. Xindao Yin
Department of radiology,
Nanjing's first hospital,
Nanjing Jiangsu, P.R.China
E-mail: y.163yy@163.com

during the diastolic phase and causes a 'milking' effect in the artery. The stenosis of the artery during the systolic phase is present to lesser extent in the superficial bridge.⁵

The predominant ethnicity presenting myocardial bridges is unknown, and high blood pressure is one of the significant factors in the formation of atherosclerosis. The purpose of this research was to compare the severity of stenosis in the proximal part of the bridge with myocardial bridges.

Material and Methods

Study population

140 patients who underwent MDCT between January 2010 and December 2012 at Nanjing's First Hospital were randomly selected for this quantitative study. Among them, 10 patients had incomplete data, and 23 patients with normal BP and stenosis were excluded. Most of the patients underwent MDCT scan due to suspicions of coronary artery disease. Among remaining 107 patients, 68 were (63.5%) males and 39 were (36.4%) females, with the average age of patients at 63.86 ± 13.01 . Most of the patients had come to the hospital with complaints of chest tightness and chest pains.

Data of each individual patient's age, sex, BP, blood cholesterol level, diabetes status, bridge length, bridge type, artery involved and stenosis were all recorded. Patients consent was taken prior to the MDCT scan and oral consent from the ethical committee was taken to carry out this research.

Stage of Hypertension	Stage 1	Stage 2
Mean Age (SD)	61.38 ± (10.38)	69.33 ± (11.96)
Sex		
Male		32 (58.1%)
Female	16 (30.7%)	23 (41.8)
HyperCholesterol		
Yes	10 (19.2%)	6 (10.9%)
No	42 (80.7%)	49 (89%)
Diabetes status		
Yes	9 (17.3%)	15 (27.2%)
No	43 (82.6%)	40 (72.7%)
Smoker		
Yes	16 (30.7%)	10 (18.1%)
No	36 (69.2%)	45 (81.8%)
Total Number (n)	52	55
Percentage (%)	48.5	51.4

Table 1: Patient baseline characteristics

SD-Standard deviation, M-Male, F-Female, Stage 1- Stage 1 hypertension and Stage 2- Stage 2 hypertension.

Procedure for the CT examination/ Image processing and analysis

Coronary angiographies were done using a Siemens CT somatom definition dual-source scanner. The image was taken from the bifurcation of the trachea through to the end of diaphragm. Contrast iopadimal was used for the scan (100ml) and 35 to 50 ml of normal saline was flushed through after the contrast was infused. Two radiologists visualized the images to evaluate the coronary arteries. Multiple Planar Reconstruction (MPR) and Curved Planar Reconstruction (CPR), were mostly used so as to accurately diagnose of the type, length, depth and location of the atherosclerosis.

Diabetes, Cholesterol and smoking

If the fasting plasma blood sugar was ≥ 7.0 or random plasma blood sugar was more than 11.1 mmol/l, the patient was said to be diabetic. If total blood cholesterol was more than 5.5 mmol/l, hypercholesterolemia was identified. In regards to smoking, occasional smoking was not considered significant to this study, but a daily smoking habit was considered positive.

Detection of MB

The detection of MB was based on the coronary artery being covered by membranous and muscular myocardium. The length of the bridge was calculated from the point where the coronary artery covered

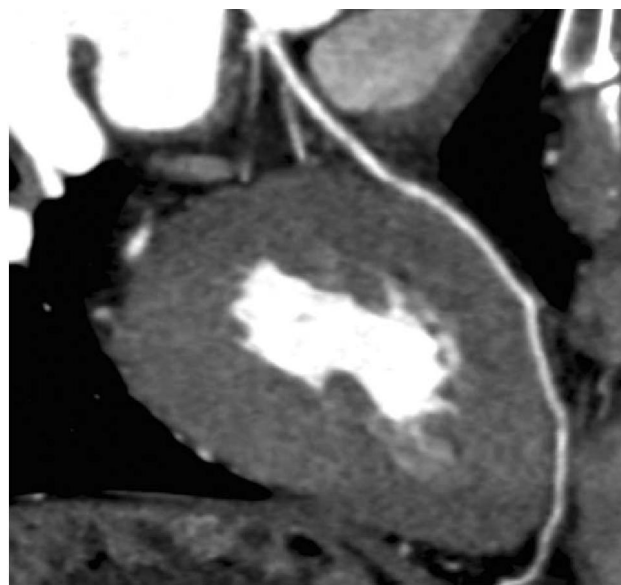


Figure 1: Showing superficial bridge with grade 1 stenosis in the artery proximal to the bridge

by the membranous or muscular myocardium began and until the covering stopped. The depth of the bridge was calculated only in cases of deep bridge, as the artery becomes embedded in muscular myocardium and this covering can be calculated by measuring the thickness of the myocardium covering the artery. In superficial bridges the covering is very thin and therefore cannot be calculated.

Detection of stenosis

By using MPR and CPR, the affected artery in the MB was visualized, and then the artery's stenosis calculated. The classification of the stenosis was based on the American Heart Association's standards, called Nobile classification. The stenosis was divided into three grades 1: <50% stenosis 2: 50-75% stenosis 3: ≥75% stenosis. This study is focused on the stenosis in the artery proximal to the bridge.

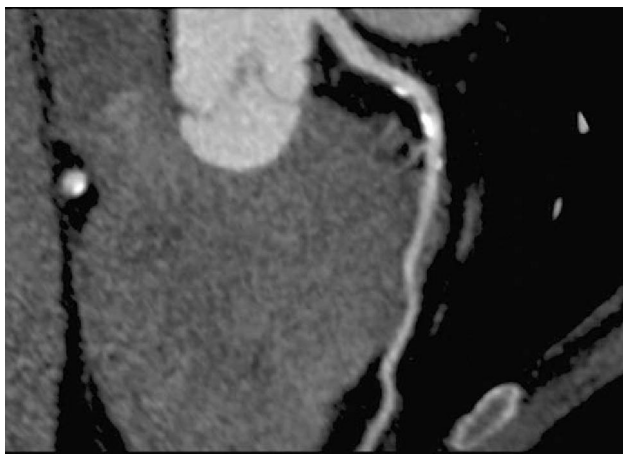

Figure 2: Showing deep bridge with grade 2 stenosis in the artery proximal to bridge

Category of blood pressure

Patients' BP was divided into four categories in accordance with the American Heart Association's standards 1. Group N (normal) 90/60 to 119/79. 2. Group P (prehypertension) 120/80 to 140/90. 3. Group 1 (stage 1) 140/90 to 160/100. 4. Group 2 (stage 2) ≥160/100 mmhg. Patients with normal and prehypertension were excluded from the study while patients whose blood pressure falls in stage 1 and stage 2 were accepted (hypertensive) for this research.

STATISTICAL ANALYSIS

Statistical analysis was done using SSPS software

11.0. If P value of less than 0.05 was considered statistically significant.

SUPERFICIAL BRIDGE				
BP	Stenosis			P Value
	1	2	3	
Stage 1	10	11	10	0.993
Stage 2	12	14	12	

Table 2: Showing the relationship between arterial stenosis and hypertension in superficial bridge patients

DEEP BRIDGE				
BP	Stenosis			P Value
	1	2	3	
Stage 1	10	11	9	0.580
Stage 2	2	2	4	

Table 3: Showing the relationship between arterial stenosis and hypertension in deep bridge patients

Results

Baseline characteristics

As seen in Table 1, there were more hypertensive males (63.5%) than females (36.4%) in this study. The mean age of stage 2 hypertensive patients was marginally higher than that of stage 1 patients (69.33 ± 11.96), and the average age of all patients included in this study is 63.86 ± 13.01 . Hypercholesterolemia (19.2%) and smoking (30.7%) was more common in stage 1 hypertension, while the stage 2 hypertension group showed a higher rate of diabetes (27.2%) as compared to stage 1 hypertension diabetics (17.3%).

Myocardial Bridge-

Superficial bridge

Among the 107 patients, superficial bridges were the most common type of bridge (69 patients or 64.4% of those studied) (Fig. 1). The mean average length of the bridge was 10.26 mm and among these patients, 65 (94.2%) of superficial bridges were in the left anterior descending (LAD) artery. The most common location of the bridge in the LAD was in the middle segment (>80%) of the artery, while the second most common location was the proximal part of the artery. Among these 69 superficial bridges, 2 (2.8%) were located in RCA and 2 (2.8%) in the diagonal arteries.

Deep bridge

38 (35.5%) patients (out of 107) suffered from myocardial deep bridge (Fig. 2), and the mean length and depth of these bridges were 7.14 and 4.29 mm respectively. More than 90% of the bridge was found in the middle segment, while the remainder was in the proximal segment. Of 38 deep bridge patients, 34 (89.4%) patients had bridges in the LAD artery, 1 (3%) patient had a bridge in the RCA, 1 (3.0%) in the diagonal arteries, and 2 (6.0%) had deep bridges in the posterior descending artery.

Stenosis and blood pressure

As shown in (Tab. 1), out of 107 patients, 52 (48.5%) had stage 1 hypertension and 55 (51.4%) patients had stage 2 hypertension. Of those myocardial superficial bridged patients in the stage 1 hypertension group (Tab. 2), patients were evenly spread across grades 1, 2 and 3 stenosis (10 to 11 patients each). In the stage 2 hypertension group, grade 2 type stenosis was most prevalent, affecting 14 of the patients.

Among the myocardial deep bridged patients (Tab. 3) in the stage 1 hypertension group, patients were again evenly spread between the three grades of stenosis (9 to 11 patients each). In the stage 2 hypertension group, stenosis was greatly reduced in comparison to all other groupings.

Statistical results

For the statistic result the Pearson test was used to determine correlations. In superficial bridge patients the p-value was 0.993, which implies that there is no significant relation between superficial bridges and proximal stenosis type in hypertensive patients. The p-value was lower in the deep bridge group (0.580), again indicating that there is no significant link between deep bridges and proximal stenosis in hypertensive patients.

Discussion

Myocardial bridge is an anatomical variation in which the artery is covered by either membranous

or muscular myocardium. The golden standard method for diagnosing MB is coronary angiography; the detection rate using CAG is between 0.5 and 29.4%.⁶ If using CAG the detection depends on the thickness of the bridge, position of the artery, and adipose tissue covering the bridge.⁷ However with the advancement in computed tomography, a non-invasive procedure, the detection rate is 3.5 to 58%, which is a broader and has higher detection rate than CAG.⁸ The detection rate of MB is higher, if the number of detectors in MDCT is increased because smaller MB can be detected.⁹ The increased spatial and contrast would make the visibility more clear and would ease in the diagnosis of MB.

In this research, it was found that around 69 (64.4%) and 38 (35.5%) of the patients were suffering from myocardial superficial and deep bridges respectively, and it has been found in previous research on superficial bridges that these are the most common bridge type, which was collaborated by this study's results, also indicating that superficial bridges are most common.¹⁰ LAD was the most common location of MB and artery involved, with MBs occurring mostly in the middle segment and less so in the proximal part. No artery was found to have two bridges. The mean length of the superficial and deep bridges was found to be 10.26 mm and 7.14 mm respectively, whereas the mean depth of the deep bridge was found to be 4.29 mm.

Atherosclerosis was present in the artery proximal to the bridge and resulted in stenosis thereby decreasing the blood flow to the myocardium. There was no sign of atherosclerosis in the tunneled artery beneath the myocardial bridge and in the distal part of the artery.^{11,12} However there is high shear stress in the tunneled artery and reduced vasoactive secretion, so that the artery is free from atherosclerosis.^{13,14} The low shear stress at the proximal part of the artery may cause lipid transfer across the arterial membrane which could lead to atherosclerosis formation.¹⁵

Endothelium is a thin layer lining the interior of blood vessels. It is an important source of mediators like nitric oxide (eNOS), Endothelin-1, thromboxane H₂, and prostoglandin A₂. The normal function of these vasoactives (increase or decreases the blood pressure) is to contribute to the relaxation and contraction of the artery. In the case of damage to

the endothelium due to high blood pressure, this could lead to narrowing and atherosclerosis initiation due to the improper secretion of these mediators by the damaged endothelium.¹⁶ In the early stages of a dysfunctional endothelium, it causes macrophage attraction and adhesion. There is also accumulation of oxidized lipid leading to fatty streaks.

In previous research it has been found that in MB, there is impaired vasoactive secretion of mediators such as nitric oxide (eNOS), angiotensin converting enzyme (ACE), and Endothelin-1 (ET-1) in the artery proximal to the bridge.^{17,18} The intimal thickness of the tunneled artery and permeability is reduced, whereas in contrast permeability in the artery proximal to the bridge is found to be increased.

An increase in blood pressure and turbulent blood flow may result in increased pressure on the intima of the artery proximal to bridge resulting in injury to the intima. This causes platelet aggression and vasospasm of the coronary artery.¹⁹ The injured intima forms into scars, causing cholesterol and other substances to become lodged onto the scar, and results in narrowing and plaque formation.

It has been documented by using intravascular ultrasound (IVUS) that there is high arterial pressure in the artery proximal to the bridge as compared to that of the aorta. It has been said in the previous studies that increases in pressure, blood flow disturbances and high wall stress in the artery proximal to bridge are the main cause for the development of atherosclerosis resulting in stenosis.²⁰ Impaired vasoactive mediator secretion, resulting in a narrowing of the artery. Both these mechanisms can result in stenosis of the affected artery, thereby reducing the blood flow.

This study is based on the hypothesis that damage to the intima of the artery proximal to the myocardial bridge is due to increased blood pressure (in hypertensive patients) which causes tears in the intima. This results in scar formation, atherosclerosis formation, and worsening of atherosclerosis in patients with pre existing atherosclerosis. These will eventually lead to stenosis.

However, according to the statistical results of this study, the superficial bridge P value (0.993) and deep bridge P value (0.580) did not show a signi-

ficant relation between stenosis and myocardial bridges in hypertensive patients. Previous research indicated that atherosclerosis forms in the artery due to high blood pressure, leading on to stenosis. However this study's results did not show a significant correlation between myocardial bridges and stenosis in hypertensive patients.

One limiting factor in this study's results may be due to smaller number of patients. It would be beneficial to continue this study with a greater number of patients. If a relationship is established between myocardial bridges and stenosis, it would then be prudent to further compare the severity of stenosis in superficial and deep bridges.

Conclusion

In this study, there was strong evidence of atherosclerosis in the proximal part of the artery, while the bridged and therefore tunneled artery showed no atherosclerosis. The results of this research therefore indicate that there is no significant relationship between the myocardial bridge and stenosis in hypertensive patients.

Conflict of interest: None

Acknowledgments

The authors wish to thank Dr. Sumedh bele and Dr. S.A.R. Ziyad for their valuable help regarding the manuscript preparation.

References

1. Moehlenkamp S, Hort W, Ge J, Erbel R. Update on myocardial bridging. *Circulation* 2002; **106**: 2616-22.
2. H. C. Reyman, "Diss. de vasis cordis propriis," *Bibliotheca Anatomica*, vol. 2, pp. 359-379, 1737. C. Portmann and J. Iwig, "Die intramural eoronarieimangiogramm," *Fortschr Rontgenstr*, 1960; **92**: 129-32.

3. W. C. Portmann and J. Iwig, "Die intramural ekoronarieimangiogramm," *Fortschr Rontgenstr*, 1960; **92**: 129-32.
4. Alegria JR, Herrmann J, Holmes DR, Lerman A, Rihal CS. Myocardial bridging. *Eur Heart J* 2005; **26**: 1159-1168.
5. Juilliere Y, Berder V, Suty-Selton C, et al. Isolated myocardial bridges with angiographic milking of the left anterior descending artery: a long-term follow-up study. *Am Heart J* 1995; **129**: 663-5.
6. Irvin RG. The angiographic prevalence of myocardial bridging. *Chest* 1982; **81**: 198-202.
7. Mo ¨hlenkamp, S., Hort, W., Ge, J., & Erbel, R. Update on myocardial bridging. *Circulation* 2002; **106**: 2616-22.
8. Noble J, Bourassa MG, Petitclerc R, et al. Myocardial bridging and milking effect of left anterior descending artery: normal variant or obstruction. *Am J Cardiol* 1976; **37**: 993-9.
9. Ko SM, Choi JS, Nam CW, Hur SH. Incidence and clinical significance of myocardial bridging with ECG-gated 16-row MDCT coronary angiography. *Int J Cardiovasc Imaging*. 2008; **24**: 445-52.
10. Ishii T, Asuwa N, Masuda S, Ishikawa Y, Kiguchi H, Shimada K. The effects of a myocardial bridge on coronary atherosclerosis and ischaemia. *J Pathol* 1998; **185**: 4-9.
11. Ishii T, Asuwa N, Masuda S, Ishikawa Y, Kiguchi H, Shimada K. Atherosclerosis suppression in the left anterior descending coronary artery by the presence of myocardial bridge: an ultra-structural study. *Mod Pathol* 1991; **4**: 424-31.
12. Ishii T, Asuwa N, Masuda S, Ishikawa Y, Kiguchi H, Shimada K. The effects of a myocardial bridge on coronary atherosclerosis and ischaemia. *J Pathol* 1998; **185**: 4-9.
13. Masuda T, Ishikawa Y, Akasaka Y, Itoh K, Kiguchi H, Ishii T. The effect of myocardial bridging of the coronary artery on vasoactive agents and atherosclerosis localization. *J Pathol* 2001; **193**: 408-41.
14. Ishii T, Asuwa N, Masuda S. The effects of a myocardial bridge on coronary atherosclerosis and ischaemia. *J Pathol*. 1998; **85**: 4-9.
15. Caro CG, Fitz-Gerald JM, Schroter RC. Atheroma and arterial wall shear; observation, correlation, and proposal of a shear dependent mass transfer mechanism for atherogenesis. *Proc R Soc Lond B Biol Sci* 1971; **177**: 109-59.
16. Vallance P, Chan N. Endothelial function and nitric oxide: clinical relevance. *Heart* 2001; **85**: 342-50.
17. Masuda T, Ishikawa Y, Akasaka Y, Itoh K, Kiguchi H, Ishii T. The effect of myocardial bridging of the coronary artery on vasoactive agents and atherosclerosis localization. *J Pathol*. 2001; **193(3)**: 408-14.
18. Lerman A, Hildebrand FL Jr, Aarhus LL, Burnett JC Jr. Endothelin has biological actions at pathophysiological concentrations. *Circulation* 1991; **83**: 1808-14.
19. Ciampricotti R, el Gamal M. Vasospastic coronary occlusion associated with a myocardial bridge. *Cathet Cardiovasc Diagn* 1988; **14**: 118-20.
20. Ge J, Jeremias A, Rupp A, Abels M, Baumgart D, Liu F et al. New signs characteristic of myocardial bridging demonstrated by intra-coronary ultrasound and Doppler. *Eur Heart J* 1999; **20**: 1707-16.