

# A CASE PRESENTED WITH DUODENAL ATRESIA SECONDARY TO ANNULAR PANCREAS AND CONSTELLATION OF OTHER ANOMALIES

Bhesham Kumar Shahani, Kiran Khurshid, Waseem Mehmood Nizamani, Fahd Haroon, Naila Younus, Sikander Shahzad

Department of Radiology, Dr. Ziauddin Hospital, Karachi, Pakistan.

PJR April - June 2016; 26(2): 129-130

## ABSTRACT

Duodenal atresia is common cause of intestinal obstruction in neonate and could be fatal if not diagnosed and surgically treated immediately. It occurs in 1-10000 live births. Diagnosis of duodenal atresia is made on plain X-ray by double bubble sign and further confirmed on contrast study. Duodenal atresia is associated with other congenital anomaly like Down's syndrome, annular pancreas, congenital heart disease, malrotation, esophageal atresia, and others.

This case report notify rare duodenal atresia secondary to annular pancreas with unusual opening of distal tracheo esophageal fistula on right side and high up esophageal atresia.

**Key words:** Duodenal atresia; Esophageal atresia; Annular pancreas

## Case Report

A primigravida woman was referred for ultrasound fetal well being (FWB) at 38 wk of gestational age. Ultra-sound examination revealed polyhydramnios. A cystic structure adjacent to distended stomach bubble (double-bubble sign) was appreciated with possible diagnosis of duodenal atresia was made. Biparietal diameter (BPD) & Femur length were appropriate for gestational age. A male baby was delivered through elective lower section C-section (LSCS) at full term with excessive salivation. A postnatal abdominal radiograph shows distended air filled stomach and proximal duodenum with no air in distal bowel loops. Nasogastric (NG) tube was passed that coiled in upper blind ended esophagus. Subsequent barium swallow examination done that confirmed esophageal atresia without communication with distal esophagus and trachea. Finally it was diagnosed as esophageal atresia with distal tracheo-

esophageal fistula and duodenal atresia. On examination patient has imper-forate anus.

Echocardiogram and ultrasound abdomen was normal. CXR shows no vertebral anomaly and twelve pairs of ribs on either side.

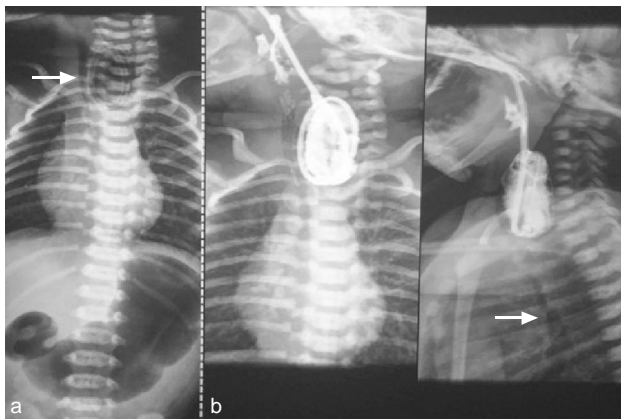
Intra-operative findings include duodenal atresia secondary to annular pancreas for which duodeno-duodenal anastomosis and gastrostomy done. Distal tracheo-esophageal fistula shows unusual opening of distal esophagus on right side that was ligated but not divided because esophageal atresial pouch was high up so no anastomosis between upper and distal esophagus done.

## Discussion

Duodenal atresia is the frequent cause of neonatal intestinal obstruction that has gained substantial importance since its first description by Calder in

**Correspondence** : Dr. Waseem Mehmood Nizamani  
Department of Radiology,  
Dr. Ziauddin Hospital,  
Karachi, Pakistan.  
Email: dr\_waseemayub@hotmail.com

Submitted 17 August 2015, Accepted 5 September 2015



**Figure 1:** (a) Collimated plain radiograph of chest and abdomen shows coiled NG tube in an air filled pouch. (white arrow). Visualized abdomen shows air filled distended stomach and proximal duodenal shadows. (b) AP and Lateral radiographs of non-ionic water soluble contrast (Iopomiro) swallow shows contrast filling of proximal esophagus which ends blindly. No communication with trachea and distal esophagus observed. Note air lucency outlining distal trachea (white arrow). Above imaging features are suggestive of esophageal atresia with distal tracheo-esophageal fistula.

1733.<sup>1</sup> Duodenal atresia is due to failure of recanalization of the bowel lumen that is a solid tube early in fetal life. Double bubble sign is worrisome sign leads to suspicion of a number of structural anomalies, which can cause duodenal obstruction. One should consider both intrinsic and extrinsic causes of duodenal obstruction. The intrinsic causes are duodenal atresia, duodenal stenosis and duodenal webs; the extrinsic causes include annular pancreas, malrotation of the gut with midgut volvulus or by Ladd bands, and preduodenal position of the portal vein. Fetal double bubble should be interpreted with caution as transient duodenal fluid accumulation and slow peristalsis can give double bubble sign.<sup>2</sup> Duodenal atresia occurs in approximately 1 in 10,000 live births.<sup>3</sup> It is associated with an approximately 5% mortality and long-term complications. Duodenal atresia was present in only about 3-6% of East Asian patients.<sup>4</sup> Duodenal atresia appears to be equally distributed between infants of both sexes, with no reported predilection for one race.<sup>5</sup> Associated congenital anomalies in duodenal atresia have been reported in more than 50% of affected patients and can include congenital heart disease, pancreatic anomalies, intestinal malrotation, esophageal atresia, imperforate anus, renal anomalies or other combinations of anomalies such as VATER/VACTERALS. Chromosomal abnormalities, particularly Down syndrome, occur in approximately 15-27% of affected patients.<sup>6</sup>

There is also an association with anomalies of the VACTERL (vertebral, anorectal, cardiac, tracheoesophageal, renal, and limb anomalies) spectrum.<sup>2</sup> The combined presence of trachea-esophageal fistula, esophageal atresia and duodenal atresia presents several management challenges. On one hand, the presence of trachea-esophageal fistula predisposes the patient to respiratory compromise from aspiration. Tracheo-esophageal fistula also fills the stomach with air that cannot traverse through the rest of the gastrointestinal tract due to the duodenal atresia. This gastric distension also cannot be decompressed with a nasogastric tube due to the esophageal atresia.<sup>4</sup> The prognosis was initially poor, but it improved peculiarly with the advent of modern anesthesia, better understanding of pathophysiology, and intensive care units. The survival is quite promising (>90%) in the entity with exception of very few cases where mortality is attributed to associated anomalies especially complex cardiac anomalies.<sup>1</sup>

## References

1. Mirza B, Sheikh A. Multiple associated anomalies in patients of duodenal atresia: A Case Series. *J Neonatal Surg.* 2012; **1(2)**: 23.
2. Traubici J. The double bubble sign. *Radiology.* 2001; **220(2)**: 463-4.
3. Christofferson M, Eziefule AA, Martinez CA, Cardwell MS. Recurrent duodenal atresia: a case report. *J Reprod Med.* 2014; **59(9-10)**: 512-4.
4. Nabzdyk CS, Chiu B, Jackson CC, Chwals WJ. Management of patients with combined tracheo-esophageal fistula, esophageal atresia, and duodenal atresia. *Int J Surg Case Rep.* 2014; **5(12)**: 1288-91.
5. Jagatiani N, Ariwala N, Shah J, Ghatala B, Patel V B. Antenatal diagnosis of duodenal atresia. *GMJ* 2009; **64(2)**: 77-8.
6. Lee S S, Hwang S T, Jang N G, Tchah H, Choi D Y, ETC. A Case of congenital duodenal web causing duodenal stenosis in a down syndrome Child: Endoscopic Resection with an Insulated-Tip Knife. *Gut Liver.* 2011; **5(1)**: 105-9.