

MYOCARDIAL BRIDGE: IMAGING AND MANAGEMENT

Gouse Mohimuddin,¹ Xindao Yin,¹ Hui Xu,¹ Mohammed M. Mohiuddin²

¹ Department of Radiology, Nanjing First Hospital, Affiliated to Nanjing Medical university, Jiangsu, P.R.China.

² Mahadevappa Rampure Medical College, Gulbarga, Karnataka, India.

PJR October - December 2013; 23(4): 136-145

ABSTRACT

Myocardial bridge (MB) is an abnormality in which a coronary artery is covered by bands of membranous or muscular myocardium instead of running on epicardium, causing compression of the affected artery and leading to stenosis (and severe stenosis in the contractile phase). As the lumen of the artery is reduced, blood flow to the myocardium is reduced, increasing the chances of ischemic events. The most common artery involved is the left anterior descending (LAD) artery, the middle segment being the most commonly affected location.

Keywords: Myocardial bridge, middle segment, stenosis, membranous, muscular myocardium, coronary angiography, atherosclerosis.

Introduction

MB is a congenital abnormality^{1,2} in which the affected artery is covered either by bands of membranous or muscular myocardium. MB was first identified in an autopsy by Reymen in 1737³ and in 1960, it was seen for the first time angiographically by Portmann and Iwig.⁴ Deep myocardial bridges cause transient stenosis of an artery during systolic phases.⁵⁻⁸ The artery most commonly involved is the LAD artery,^{9,10} with the most commonly affected location being the mid segment and the next most common being the distal segment.¹¹⁻¹⁴ Lazoura, however, showed that in 184 cases of MB affecting the LAD artery, 125 occurred in the proximal segment, 53 in the mid segment and 6 in the distal segment.¹⁵ The detection of MB through autopsy ranging from 5.4 to 85.7% is higher than by coronary angiography (CAG) and multidetector or computed tomography (MDCT),^{16,17} though with MDCT, the detection rate is higher because of better resolution. The detection rate is much higher on autopsy and MBs as small as 200 µm can be detected. MBs may

trigger many cardiac problems such as ventricular arrhythmias, heart blocks and myocardial ischemia (MI).^{18,19}

The Anatomy of MB

By using MDCT and CAG, the anatomical properties of the MB can be calculated, including the artery involved, its length and depth. The artery most commonly involved in MB is the LAD artery,²⁰ the segments most commonly affected being middle > distal > proximal.²¹⁻²³ Occurrence of MB is less common in right coronary and circumflex arteries.²⁴ There is formation of atherosclerosis in the artery proximal to the bridge and the length and depth of the bridge play an important role in determining the atherosclerosis suppression ratio.²⁵ MB can be divided into two types: superficial bridges and deep bridges. With superficial bridges, the affected artery is covered by membranous myocardium and with deep bridges, the artery is covered by muscular myocardium.²⁶ The length and depth of the bridge

Correspondence : Dr. Gouse Mohimuddin
Department of Radiology,
Nanjing First Hospital, Affiliated to
Nanjing Medical university, Jiangsu,
P.R.China. Email:gouseustad@hotmail.com

Submitted 4 January 2015, Accepted 24 February 2015

can be calculated by measuring the length and thickness of the myocardium covering the bridge. A single artery may have two bridges. The lengths of MBs vary from 3 mm to 69 mm and depths vary from 1.5 mm to 6 mm.^{27,28} With superficial bridges, depth calculation is difficult as the covering is small. Longer and thicker MBs tend to be located more towards the proximal segment of LAD artery.²⁹

Radiological Evaluation

The detection rate of MB depends on the diagnostic method used.^{30,31}

CAG

The gold-standard method for detecting MB is conventionally CAG, which has a detection rate of 0.4-15.8%. Angiographic findings show systolic reduction in the diameter of the bridged artery and persistent reduction during the diastolic phase. In MB, the artery is surrounded by the myocardium, which compresses the artery during the contraction of the heart, leading to transient stenosis of the affected artery. During heart's relaxation phase, the artery relaxes, giving a "milking effect" (systolic squeezing effect) that is a diagnostic standard for diagnosing MB with CAG³² (Fig. 1). Most researchers

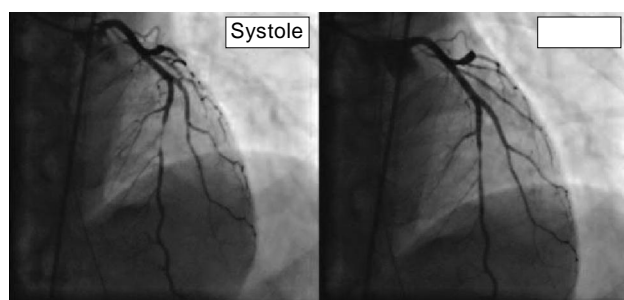


Figure 1: Coronary angiogram (CAG) showing a segment of LAD in MB with "milking effect" during systole (arrows).

believe that superficial bridges do not produce such effects, though the reason is not yet known. As such, superficial bridges have a higher chance of being missed with CAG.³³ In MB, the artery runs under the myocardium, giving it a 'U-shaped' appearance. The frequency of detection with CAG depends on

the thickness, position and adipose covering the artery³⁴ and sometimes MB can be missed because of stenotic lesions proximal to the bridge. A bridge is said to be partial when the affected artery has covering >75% but less than 100% and complete when the artery is fully embedded in myocardium.

MDCT

With previous scanners, detection of coronary abnormalities was difficult due to the use of thick scan slices. However, we are now able to utilize thinner scan slices to evaluate coronary artery abnormalities using MDCT. MDCT is non-invasive and is very useful in calculating the length and depth of a bridge. When the bridge covering is thin, they can be calculated with MDCT rather than CAG and the detection rate of 3.5-58% is higher than that of CAG. With the use of multiplanar reformation and curved planar reformation in MDCT, we can calculate luminal diameter, course of the affected artery and the anatomical relation of coronary arteries. With superficial bridges, the covering is thin and might be missed with CAG because it does not show bridge compression, but with MDCT we can see the membranous myocardium covering the artery. A bridge is said to be deep when it has ≥ 2 mm covering the artery (Fig. 2). A study has mentioned that with the use of MDCT, a greater presence of calcium deposition in the MB-free coronary artery than the bridged artery has been observed, which is dependent upon the surrounding adipose.³⁵

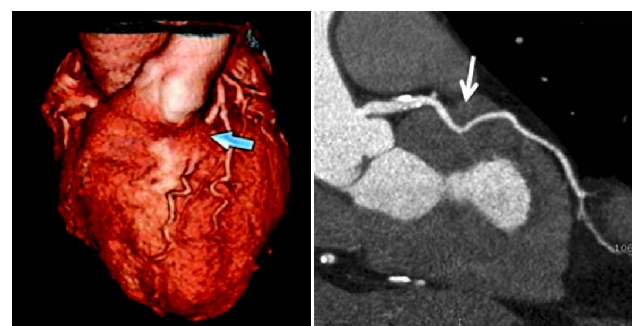

Figure 2: Multi Detector CT (MDCT) angiogram showing proximal LAD segment (arrows) in a deep myocardial bridge (> 2 mm).

IVUS and Doppler

We can determine changes in blood flow and velocity patterns with IVUS and Doppler. Ge et al. used IVUS/

Doppler to observe increased pressure in the artery proximal to the bridged LAD artery in MB patients and reduced pressure in the distal segment when compared with aortic pressure. The authors concluded that a rise in arterial pressure, high wall stress and change in blood flow could have been the reasons for the development of atherosclerosis proximal to the bridge.³⁶ The bridged artery shows delayed increase in diastolic diameter in the heart's relaxation phase and this has an effect on the perfusion of myocardium, particularly during increased heart rate. Kluese et al. used CAG and intracoronary Doppler imaging to check the blood flow pattern, velocity, pressure and flow reserve in the coronary artery. In 12 MB patients, they observed a rise in pressure during the contractile phase, decrease in the diastolic diameter of the artery, increased blood flow velocities, retrograde flow and reduced flow reserve. In a study of 62 patients that used IVUS and CAG, positive systolic compression of the bridged artery was observed. Using Doppler to observe the whole cardiac cycle, high lucent half-moon appearances were found in the bridged artery.⁵⁸ Half-moon signs are not a 100% reliable diagnostic, as the compression of MB has been detected in the absence of such half-moon signs using IVUS.³⁷ The peak velocity in the bridged artery was significantly higher than in the proximal and distal segments. In the early diastolic phase, there was a characteristic 'fingertips' appearance within the bridged artery that is characteristic of MB. This was observed in 87% of the patients³⁸ and represents an abrupt reduction in myocardial tension and resistance in microcirculation.

Histology

Brodsky et al. carried out histological examinations on six autopsy hearts where the LAD artery had taken an intramural course (deep myocardial bridges) and compared the presence of myocardial fibrosis with ten age-matched controls. They observed increased interstitial fibrosis in hearts with MB.³⁹ The change in endothelial cell morphology in bridged arteries might be due to hemodynamical changes like high shear stress in the tunneled artery and low shear stress in the artery proximal to the bridge, causing atherosclerosis by lipid transfer under the

intima.⁴⁰ Previous researchers showed that intimal thickening is reduced in arteries where blood flow velocity is high and high shear stress is present, thickening increasing in regions of low wall shear stress.⁴¹ Risse and Weiler showed that the intima in the bridged artery is thinner (66.3 μ) than in the artery proximal to the bridge (406.6 μ). Histological studies of the intima of bridged arteries have revealed an abundance of interarterial spiraled collagen and contractile smooth muscle cells. There was no synthesis-type smooth muscle, which has the function of production and proliferation of fibrils and elastic fibers, this has an effect on the process of atherosclerosis.⁴² The proximal part of the LAD artery in MB patients shows endothelial cells being polygonal in shape and arranged in a high shear-like pattern, as compared with the endothelial cells in the tunneled artery, where the endothelial cells become spindle-shaped and regularly engorged in the direction of blood flow. This is related to change in the shear stress on both sides.^{43,44} Similar changes in endothelial cell pattern were observed in rabbits fed with fat.⁴⁵ The surrounding adipose does not play a significant role in providing cushion or pathogenesis of atherosclerosis in the LAD artery and MB length and depth are independent factors that do not affect the atherosclerosis ratio.⁴⁶

Pathophysiology of Atherosclerosis

It is known that changes in blood pressure are responsible for the pressure gradient, which in turn could lead to stress on the arterial wall. It has been said in previous research that endothelial dysfunction is signaled by impaired endothelium-dependent vasodilatation, which is one factor in initiating the pathogenesis of atherosclerosis. Despite the relation between MB and endothelial dysfunction, the bridged artery is free from atherosclerosis.⁴⁷ In MB, the arterial pressure of the bridged artery is greater than the aortic pressure due to the surrounding myocardium compressing the artery, particularly in the systolic phase. The increase in arterial pressure causes a reduction of mural stress in the bridged artery. This low mural stress may be the cause for free atherosclerosis of the bridged artery. The reduction of mural stress depends on how deep the

artery is embedded. Robicsek & Thubrikar showed that a reduction in mural stress has a significant effect on the surrounding tissue's pressure, leading to transmural gradient reduction. Mural stress therefore protects the bridged artery from atherosclerosis.⁴⁸ There are various types of adipokines released from the adipose around the coronary arteries, which play a role in the development of local atherosclerosis. It is not well understood whether the adipokines are released from the adipose tissue surrounding the artery or from the blood within the artery.⁴⁹⁻⁵¹

Vasoactive Agents

Masuda et al. showed the relation between endothelin-1 (ET-1), angiotensin converting enzyme (ACE) and endothelial nitric oxide synthase (eNOS), MB and atherosclerosis. There was no atherosclerosis in the intima of the bridged artery, which differed from arteries on either side of the bridged artery. ET-1 affected the process of atherosclerosis at all stages,⁵²⁻⁵⁴ having vasoconstrictor and mitogenic effects on vascular smooth muscle cells which caused their migration and growth. The vasoactive levels were increased on either side of the bridge (proximal and distal segments) and reduced in the bridged artery. The increase in secretion of the vasoactive may be one of factors for the pathogenesis of atherosclerosis⁵⁵ and the altered secretion pattern might be due to altered hemodynamic stress on the vascular wall.⁵⁶ In an autopsy, a cross section of an MB-affected LAD artery was analyzed. The artery was stained with antibodies for eNOS, ET-1 and ACE. The amount of atherosclerosis in the cross-section was calculated so as to find the relation between the vasoactive and atherosclerosis. The presence of both atherosclerosis and the vasoactive were diminished in the bridged artery. There was impairment in endothelium-related vaso relaxation of the bridged artery, possibly due to the stress placed on the artery by the surrounding myocardium compression which could impair normal endothelium function. There was more vasoconstriction in response to acetylcholine in the MB-affected artery and greater spasm as compared to normal arteries. These two factors could be the reasons for coronary events in MB patients.⁵⁷

Clinical Manifestation and Complication

Clinical significance is based mostly upon the stenosis caused by the compression of the artery and atherosclerosis formation. Normally, 15% of blood flow occurs during the systolic phase of the heart, but in MB, the diameter of the artery is affected during both the systolic and diastolic phases, leading to reduced blood flow. In many autopsies, a high rate of MB is found, which shows that MB could be asymptomatic in most patients. In many cases, MB is incidentally found and patients have a good long-term survival rate.⁵⁸ Though most superficial bridges are asymptomatic, deep bridges are usually symptomatic due to the myocardial covering.^{59,60}

The length and depth of the bridge play an important role in whether or not clinical symptoms present, longer and deeper bridges with greater compression commonly being found in symptomatic patients.⁶¹ The compression of the artery also plays an important role, a study showing that artery compression >75% of its diameter results in myocardial ischemia.⁶² Doppler shows an initial reduction in the diameter at the end of systole and an abrupt increase in the diameter of the artery during diastole and there is reduced blood reserve in the bridged artery. In tachycardia, contraction of the heart reduces blood flow, which leads to the development of ischemic symptoms.⁶³ This could be the cause for sudden death in young athletes.⁶⁴ During the systolic phase, this may cause damage to the intima in the proximal segment of the artery and could lead to platelet aggregation and vasospasm of the bridged artery, causing acute coronary syndrome. MB affected arteries are more prone to spasm than healthy arteries (73% vs 40%).⁶⁵⁻⁶⁷ Ge et al. showed that 12 out of 14 patients had plaque formation in the artery proximal to the bridge. This might cause thrombus and may form a micro-embolism if it detaches. The most common cause for myocardial infarction (MI) is atherosclerosis.⁶⁸ The endothelial function was severely impaired in the artery proximal to the bridge. In a study, 300 individuals had coronary heart disease-related deaths, of which 39.9% were due to MB. Most were sudden cardiac deaths (69%).⁶⁹ Though there is a great deal of literature

on the relationship between stenosis and myocardial events, there are many cases where MB can lead to conduction abnormalities, atrioventricular blocks, ventricular tachycardia and cardiac arrhythmias.

Treatment

MEDICAL

The anatomical properties of MB affect treatment and patients' recoveries most in surgical procedures.⁷⁰ B-blockers are the most common choice for the symptomatic treatment of MB patients.⁷¹ B-blockers function by reducing heart rate, which leads to reduced compression on the artery and increases the arterial diameter, thereby increasing the blood flow.^{72,73} In patients with contraindications for B-blockers, we can use either C-channel blockers or nitrates. C-channel blockers in particular can be used for patients with vasospasm and nitrates are useful in reducing symptoms of angina, though nitrates cause coronary compression and result in diameter reduction of the coronary artery.⁷⁴⁻⁷⁶

STENT PLACEMENT

Stent placement has been very useful in MB patients as the artery is compressed by myocardium. Stent is mainly used with patients who have a resistance to drugs and severe compression and occlusion of an artery. The stent directly increases the diameter of the compressed artery and increases the blood flow to the myocardium.^{77,78} During the placement of the stent, perforation of the artery can be caused by the large size of the stent, the small lumen of the tunnel artery as compared to the proximal artery and a thin arterial wall.⁷⁹ Post-operative complications can result from high-intensity compression by the myocardium, causing the stent to fracture and causing re-stenosis.⁸⁰ There is a higher risk of lesion in the LAD artery and re-stenosis during or after stent placement.⁸¹ The stent in the MB segment may be subjected to abnormal shear stress because of squeezing of the vessel wall between the deployed stent and the MB – called the “sandwich effect”. This results in neo-intimal proliferation and vasoactive substance production.⁸² There are increased chances of stent fracture in MB patients as compared with non-MB patients.⁸³ Metal stents are more prone to

re-stenting than drug eluting stent (DES), making them a good choice for patients with MB.^{84,85}

SURGICAL TREATMENT

Since 1975, surgical myotomy has proved to be very effective in patients with repeated symptoms due to deeply-situated MBs and in patients who are not suitable for stent placement.^{86,87} Surgical myotomy relieves the pressure from the myocardium and increases the diameter of the coronary artery, leading to increased blood flow.⁸⁸ The long-term prognosis of MB patients undergoing myotomy are very good.⁸⁹ The choice between surgical myotomy and coronary graft depends upon the anatomical properties of the MB. If there is the presence of atherosclerosis in the MB-affected artery and the artery is located too deep in the myocardium, then coronary graft is better.⁹⁰ In symptomatic MB patients, surgical myotomy plays an important role with usage of medication and has good results in patients with hypertrophic cardiomyopathy.⁹¹ In preoperative surgical myotomy, there are few complications like artery perforation.^{92,93} In cases where the LAD artery is situated deep in the ventricular myocardium, there is the risk of injuring the right ventricle and treating long bridges runs the risk of perforating the affected coronary artery. Post-operative scarring may result when there is compression of the coronary artery.⁹⁴

References

1. Angelini P, Velasco JA, Flamm S. Coronary anomalies: incidence, pathophysiology, and clinical relevance. *Circulation* 2002; **105**: 2449-54.
2. Angelini P, Trivellato M, Donis J, Leachman RD. Myocardial bridges: a review. *Prog Cardiovasc Dis* 1983; **26**: 75-88.
3. Reyman HC. Diss. de vasis cordis propriis. *Bibl Anat* 1737; **2**: 359-79.
4. Portmann WC, Iwig J. Die intramurale koronarie im angiogramm. *Fortschr Rontgenstr* 1960; **92**: 129-32.



5. Bestetti RB, Oliveira JS. Myocardial bridging of a coronary artery: a not-so-benign anomaly. *Chest* 1989; **95**: 706-7.
6. Tauth J, Sullebarger T. Myocardial infarction associated with myocardial bridging: case history and review of the literature. *Cathet Cardiovasc Diagn* 1997; **40**: 364-7.
7. Hillman ND, Mavroudis C, Backer CL, Duffy CE. Supraarterial decompression myotomy for myocardial bridge in a child. *Ann Thorac Surg* 1999; **68**: 244-6.
8. Roul G, Sens P, Germain P, Barciss P. Myocardial bridge as a cause of acute transient left heart dysfunction. *Chest* 1999; **116**: 574-80.
9. Ishii T, Asuwa N, Masuda S, Ishikawa Y. The effects of a myocardial bridge on coronary atherosclerosis and ischaemia. *J Pathol*. 1998; **185**: 4-9.
10. Zeina AR, Odeh M, Blinder J, Rosenschein U, Barmeir E. Myocardial bridge: Evaluation on MDCT. *Am J Roentgenol* 2007; **188**: 1069-73.
11. Channer KS, Bukis E, Hartnell G, Rees JR. Myocardial bridging of the coronary arteries. *Clin Radiol* 1989; **40**: 355-9.
12. Kim JW, Park CG, Suh SY, Choi CU, Kim EJ, Rha SW, et al. Comparison of frequency of coronary spasm in Korean patients with versus without myocardial bridging. *Am J Cardiol* 2007; **100**: 1083-6.
13. Kantarci M, Duran C, Durur I, Alper F, Onbas O, Gulbaran M, et al. Detection of myocardial bridging with ECG-gated MDCT and multiplanar reconstruction. *Am J Roentgenol* 2006; **186**: 391-4.
14. Lubarsky L, Gupta MP, Hecht HS. Evaluation of myocardial bridging of the left anterior descending coronary artery by 64-slice multidetector computed tomographic angiography. *Am J Cardiol* 2007; **100**: 1081-2.
15. Lazoura O, Kanavou T, Vassiou K, Gkiokas S, Fezoulidis IV. Myocardial bridging evaluated with 128-multi detector computed tomography coronary angiography. *Surg Radiol Anat* 2010; **32**: 45-50.
16. Polacek P. Relation of myocardial bridge and loops on the coronary arteries to coronary occlusions. *Am Heart J* 1961; **61**: 44-52.
17. Irvin RG. The angiographic prevalence of myocardial bridging. *Chest* 1982; **81**: 198-202.
18. Kalaria VG, Koradia N, Breall JA. Myocardial bridge: A clinical review. *Cathet Cardiovasc Interv* 2002; **57**: 552-6.
19. Gow RM. Myocardial bridging: Does it cause sudden death? *Card Electrophysiol Rev* 2002; **6**: 112-4.
20. Kramer JR, Kitazume H, Proudfit WL, Sones FM Jr. Clinical significance of isolated coronary bridges: Benign and frequent condition involving the left anterior descending artery. *Am Heart J* 1982; **103**: 283-8.
21. Kantarci M, Duran C, Durur I, Alper F, Onbas O, Gulbaran M, et al. Detection of myocardial bridging with ECG-gated MDCT and multiplanar reconstruction. *Am J Roentgenol* 2006; **186**: 391-4.
22. Liu SH, Yang Q, Chen J, Wang X, Wang M, Liu C. Myocardial bridging on dual-source computed tomography: Degree of systolic compression of mural coronary artery correlating with length and depth of the myocardial bridge. *Clin Imaging* 2010; **34**: 83-8.
23. Kim SY, Lee YS, Lee JB, Ryu JK, Choi JK, Chang SG, et al. Evaluation of myocardial bridge with multidetector computed tomography. *Circ J* 2010; **74**: 137-41.
24. Garg S, Brodison A, Chauhan A. Occlusive systolic bridging of circumflex artery. *Cathet Cardiovasc Diagn* 2000; **51**: 477.

25. Ishikawa Y, Akasaka Y, Ito K, et al. Significance of anatomical properties of myocardial bridge on atherosclerosis evolution in the left anterior descending coronary artery. *Atherosclerosis* 2006; **186**: 380-9.
26. Ferreira AG Jr, Trotter SE, Konig B Jr, Decourt LV, Fox K, Olsen EG. Myocardial bridge: morphological and Functional aspects. *Br Heart J* 1991; **61**: 364-7.
27. Polacek P, Kralovec H. Relation of myocardial bridges and loops on the coronary arteries to coronary occlusions. *Am Heart J* 1961; **61**: 44-52.
28. Edward JC, Burnsides C, Swarm RL, Lansing AJ. Arteriosclerosis in the intramural and extramural portions of coronary arteries in human heart. *Circulation* 1956; **13**: 235.
29. Ishii T, Hosoda Y, Osaka T, Imai T, Shimada H, Takami A, et al. The significance of myocardial bridge upon atherosclerosis in the left anterior descending coronary artery. *J Pathol* 1986; **148**: 279-91.
30. Konen E, Goitein O, Sternik L, Eshet Y, Shemesh J, Di Segni E. The prevalence and anatomical patterns of intramuscular coronary arteries a coronary computed tomography angiographic study. *J Am Col Cardiol* 2007; **49**: 587-93.
31. Möhlenkamp S, Hort W, Ge J, Erbel R. Update on myocardial bridging. *Circulation* 2002; **106**: 2616-22.
32. Amplatz K, Anderson R. Angiographic appearance of myocardial bridging of the coronary artery. *Invest Radiol* 1968; **3**: 213-5.
33. Kim PJ, Hur G, Kim SY, Namgung J, Hong SW, Kim YH, et al. Frequency of myocardial bridges and dynamic compression of epicardial coronary arteries. *Circulation* 2009; **119**: 1408-16.
34. Möhlenkamp S, Hort W, Ge J, & Erbel R. (2002). Update on myocardial bridging. *Circulation*, 106, 2616-22.
35. Verhagen SN, Rutten A, Meijs MF, et al. Relationship between myocardial bridges and reduced coronary atherosclerosis in patients with angina pectoris. *Int J Cardiol* 2012 Mar 3 [PMID: 22386701].
36. Ge J, Erbel R, Gorge G, Haude M, Meyer J. High wall shear stress proximal to myocardial bridging and atherosclerosis: intracoronary ultrasound and pressure measurements. *Br Heart J* 1995; **73**: 462-5.
37. Herrmann J, Higano ST, Lenon RJ, Rihal CS, Lerman A. Myocardial bridging is associated with alteration in coronary vasoreactivity. *Eur Heart J*. 2004; **25**: 2134-42.
38. Ge J, Jeremias A, Rupp A, Abels M, Baumgart D, Liu F, Haude M, Gorge G, von Birgelen C, Sack S, Erbel R. New signs characteristic of myocardial bridging demonstrated by intracoronary ultrasound and doppler. *Eur Heart J*. 1999; **20**: 1707-16.
39. Brodsky SV, Roh L, Ashar K, Braun A, Ramaswamy G: Myocardial bridging of coronary arteries: A risk factor for myocardial fibrosis? *Int J Cardiol*. 2008; **124**: 391-2.
40. Caro CG, Fitz-Gerald JM, Schroter RC. Atheroma and arterial wall shear. Observation, correlation and proposal of a shear dependent mass transfer mechanism for atherogenesis. *Proc R Soc Lond B Biol Sci* 1971; **177**: 109e59.
41. Cheng C, Tempel D, Rien van Haperen R, et al. Atherosclerotic lesion size and vulnerability are determined by patterns of fluid shear stress. *Circulation* 2006; **113**: 2744–53.
42. Campbell GR, Campbell JH. Smooth muscle phenotypic changes in arterial wall homeostasis: implications for the pathogenesis of atherosclerosis. *Mol Pathol* 1988; **48**: 1-11.
43. Ishii T, Asuwa N, Masuda S, Ishikawa Y, Kiguchi H, Shimada K. Atherosclerosis suppression in the left anterior descending coronary artery by the presence of myocardial bridge: an ultrastructural study. *Mod Pathol* 1991; **4**: 424-31.

44. Ishii T, Asuwa N, Masuda S, et al. The effects of a myocardial bridge on coronary atherosclerosis and ischaemia. *J Pathol* 1998; **185**: 4-9.
45. Ishikawa Y, Ishii T, Asuwa N, Masuda S. Absence of atherosclerosis evolution in the coronary arterial segment covered by myocardial tissue in cholesterol-fed rabbits. *Virchows Arch* 1997; **430**: 163-71.
46. Association of variance in anatomical elements of myocardial bridge with coronary atherosclerosis Iuchi A., Ishikawa Y., Akishima-Fukasawa Y., Fukuzawa R., Akasaka Y., Ishii T. *Atherosclerosis* 2013; **227(1)**: 153-8.
47. Kim JW, Seo HS, Na JO, Suh SY, Choi CU, Kim EJ, et al. Myocardial bridging is related to endothelial dysfunction but not to plaque as assessed by intracoronary ultrasound. *Heart*. 2008; **94(6)**: 765-9.
48. Robicsek F, Thubrikar MJ. The freedom from atherosclerosis of intramyocardial coronary arteries: reduction of mural stress - a key factor. *Eur J Cardiothorac Surg*. 1994; **8(5)**: 228-35.
49. Verhagen SN, Visseren FL. Perivascular adipose tissue as a cause of atherosclerosis. *Atherosclerosis* 2011; **214**: 3-10.
50. Payne GA, Kohr MC, Tune JD. Epicardial perivascular adipose tissue as a therapeutic target in obesity-related coronary artery disease. *Br J Pharmacol* 2012; **165**: 659-69.
51. Silaghi AC, Pais R, Vallea A, et al. Epicardial adipose tissue and relationship with coronary artery disease. *Cent Eur J Med* 2011; **6**: 251-62.
52. Lerman A, Edwards BS, Hallett JW, Heublein DM, Sandberg SM, Burnett JC Jr. Circulating and tissue endothelin immunoreactivity in advanced atherosclerosis. *N Engl J Med* 1991; **325**: 997-1001.
53. Lerman A, Hildebrand FL Jr, Aarhus LL, Burnett JC Jr. Endothelin has biological actions at pathophysiological concentrations. *Circulation* 1991; **83**: 1808-14.
54. Ihling C, Szombathy T, Bohrmann B, Brockhaus M, Schaefer HE, Loeffler BM. Coexpression of endothelin-converting enzyme-1 and endothelin-1 in different stages of human atherosclerosis. *Circulation* 2001; **104**: 864-9.
55. Teragawa H, Fukuda Y, Matsuda K, Hirao H, Higashi Y, Yamagata T, et al. Myocardial bridging increases the risk of coronary spasm. *Clin Cardiol*. 2003; **26(8)**: 377-83.
56. Masuda T, Ishikawa Y, Akasaka Y, Itoh K, Kiguchi H, Ishii T. The effect of myocardial bridging of the coronary artery on vasoactive agents and atherosclerosis localization. *J Pathol*. 2001; **193(3)**: 408-14.
57. Herrmann J, Higano ST, Lenon RJ, Rihal CS, Lerman A. Myocardial bridging is associated with alteration in coronary vasoreactivity. *Eur Heart J*. 2004; **25(23)**: 2134-42.
58. Julliere Y, Berder V, Suty-Selton C, Buffet P, Danchin N, Cherrier F. Isolated myocardial bridges with angiographic milking of the left anterior descending artery: a long-term follow-up study. *Am Heart J* 1995; **129**: 663-5.
59. Lujinovic A, Ovcina F, Cihlarz Z, Selak I, Kulenovic A. The effects of myocardial bridging on the incidence of coronary arteriosclerosis. *Med Arch* 2006; **60**: 275-8.
60. Bonvini RF, Alibgovic J, Perret X, Keller PF, Camenzind E, Verin V, et al. Coronary myocardial bridge: an innocent bystander? *Heart Vessels* 2008; **23**: 67-70.
61. Schwarz ER, Klues HG, vom Dahl J, Klein I, Krebs W, Hanrath P. Functional characteristics of myocardial bridging: a combined angiographic And
62. Noble J, Bourassa MG, Petitclerc R, Dyrda I. Myocardial bridging and milking effect of the left anterior descending coronary artery: Normal variant or obstruction? *Am J Cardiol* 1976; **37**: 993-9.

63. Rossi L, Dander B, Nidasio GP, Arbustini E, Paris B, Vassanelli C et al. Myocardial bridges and ischemic heart disease. *Eur Heart J* 1980; **1**: 239-45.
64. Corrado D, Thiene G, Cocco P, Frescura C. Non-atherosclerotic coronary disease and sudden death in the young. *Br Heart J* 1992; **68**: 601-7.
65. Ciampicotti R, el Gamal M. Vasospastic coronary occlusion associated with a myocardial bridge. *Cathet Cardiovasc Diagn* 1988; **14**: 118-20.
66. Gertz SD, Uretsky G, Wajnberg RS, Navot N, Gotsman MS. Endothelial cell damage and thrombus formation after partial arterial constriction: relevance to the role of coronary artery spasm in the pathogenesis of myocardial infarction. *Circulation* 1981; **63**: 476-86.
67. Maseri A, Chierchia S. Coronary artery spasm: demonstration, definition, diagnosis, and consequences. *Prog Cardiovasc Dis* 1982; **25**: 169-92.
68. Duygu H, Zoghi M, Nalbantgil S, Kirilmaz B, Turk U. Myocardial bridge: a bridge to coronary atherosclerosis. *Anadolu Kardiyol Derg* 2007; **7**: 12-6.
69. Rozenberg VD, Nepomnyashchikh LM. Pathomorphology and pathogenic role of myocardial bridges in sudden cardiac death. *Bull Exp Biol Med* 2004; **138**: 87-92.
70. Kim SS, Jeong MH, Kim HK, Kim MC, Cho KH, Lee MG, et al. Long-term clinical course of patients with isolated myocardial bridge. *Circ J* 2010; **74**: 538-43.
71. Bestetti RB, Finzi LA, Amaral FTV, Secches AL, Oliveira JSM. Myocardial bridging of coronary arteries associated with an impending acute myocardial infarction. *Clin Cardiol* 1987; **10**: 129-31.
72. Nair CK, Dang B, Heintz MH, Sketch MH. Myocardial bridges: Effect of propranolol on systolic compression. *Can J Cardiol* 1986; **2**: 218-21.
73. Schwarz ER, Klues HG, vom Dahl J, Klein I, Krebs W, Hanrath P. Functional, angiographic and intracoronary Doppler flow characteristics in symptomatic patients with myocardial bridging: Effect of short-term intravenous beta-blocker medication. *J Am Coll Cardiol* 1996; **27**: 1637-45.
74. Noble J, Bourassa MG, Petitclerc R, Dyrda I. Myocardial bridging and milking effect of the left anterior descending coronary artery: Normal variant or obstruction? *Am J Cardiol* 1976; **37**: 993-9.
75. Hongo Y, Tada H, Ito K, Yasumura Y, Miyatake K, Yamaguchi M. Augmentation of vessel squeezing at coronary-myocardial bridge by nitroglycerin: Study by quantitative coronary angiography and intravascular ultrasound. *Am Heart J* 1999; **138**: 345-50.
76. Joyal D, Charbonneau F. Vasospasm and myocardial bridge. *Can J Cardiol* 2003; **19**: 1440-2.
77. Klue HG, Schwarz ER, vom Dahl J, Reffelmann T, Reul H, Potthast K, et al. Disturbed intracoronary hemodynamics in myocardial bridging: Early normalization by intracoronary stent placement. *Circulation* 1997; **96**: 2905-13.
78. Haager PK, Schwarz ER, vom Dahl J, Klues HG, Reffelmann T, Hanrath P. Long term angiographic and clinical follow up in patients with stent implantation for symptomatic myocardial bridging. *Heart* 2000; **84**: 403-8.
79. Berry JF, von Mering GO, Schmalfuss C, Hill JA, Kerensky RA. Systolic compression of the left anterior descending coronary artery: A case series, review of the literature, and therapeutic options including stenting. *Cathet Cardiovasc Interv* 2002; **56**: 58-63.
80. Tandar A, Whisenant BK, Michaels AD. Stent fracture following stenting of a myocardial bridge: Report of two cases. *Cathet Cardiovasc Interv* 2008; **71**: 191-6.

81. Ross MJ, Herrmann HC, Moliterno DJ, Blankenship JC, Demopoulos L, DiBattiste PM, Ellis SG, Ghazzal Z, Martin JL, White J, Topol EJ. Angiographic variables predict increased risk for adverse ischemic events after coronary stenting with glycoprotein IIb/IIIa inhibition: results from the TARGET trial. *J Am Coll Cardiol* 2003; **42**: 981-8.
82. Kursaklioglu H, Barcin C, Iyisoy A, Kose S, Amasyali B, Isik E. Angiographic restenosis after myocardial bridge stenting. *Jpn Heart J* 2004; **45**: 581-9.
83. Kursaklioglu H, Barcin C, Iyisoy A, Kose S, Amasyali B, Isik E. Angiographic restenosis after myocardial bridge stenting: A comparative study with direct stenting of de-novo atherosclerotic lesions. *Jpn Heart J* 2004; **45**: 581-9.
84. Moses JW, Leon MB, Popma JJ, Fitzgerald PJ, Holmes DR, O'Shaughnessy C, et al. Sirolimus-eluting stents versus standard stents in patients with stenosis in a native coronary artery. *N Engl J Med* 2003; **349**: 1315-23.
85. Singh H, Singh C, Kumar A, Aggarwal N, Banerji A. Acute myocardial infarction secondary to myocardial bridge treated with drug-eluting stent. *Indian Heart J* 2005; **57**: 734-7.
86. Binet JP, Planche C, Leriche H, Raza A, Kone A, Piot C, et al. Myocardial bridge compressing the anterior inter-ventricular artery: Apropos of a successfully operated case. *Arch Mal Coeur Vaiss* 1975; **68**: 85-90.
87. Tio RA, Ebels T. Ventricular septal rupture caused by myocardial bridging. *Ann Thorac Surg* 2001; **72**: 1369-70.
88. Iversen S, Hake U, Mayer E, Erbel R, Diefenbach C, Oelert H. Surgical treatment of myocardial bridging causing coronary artery obstruction. *Scand J Thorac Cardiovasc Surg* 1992; **26**: 107-11.
89. Rezayat P, Hassan D, Amirreza S, Susan H. Myocardial bridge: Surgical outcome and midterm follow up. *Saudi Med J* 2006; **27**: 1530-3.
90. Parashara DK, Ledley GS, Kolter MN, Yazdanfar S. The combined presence of myocardial bridging and fixed coronary artery stenosis. *Am Heart J* 1993; **125**: 1170-2.
91. Hillman ND, Mavroudis C, Backer CL, Duffy CE. Supraarterial decompression myotomy for myocardial bridging in a child. *Ann Thorac Surg* 1999; **68**: 244-6.
92. Rezayat P, Hassan D, Amirreza S, Susan H. Myocardial bridge: Surgical outcome and midterm follow up. *Saudi Med J* 2006; **27**: 1530-3.
93. Walters DL, Aroney CN, Radford DJ. Coronary stenting for a muscular bridge in a patient with hypertrophic obstructive cardiomyopathy. *Cardiol Young* 2003; **13**: 377-9.
94. Baryalei MM, Tirilomis T, Buhre W, Kazmaier S, Schoendube FA, Aleksic I. Off-pump supraarterial decompression myotomy for myocardial bridging. *Heart Surg Forum* 2005; **8**: 49-54.