

CARPAL TUNNEL SYNDROME IN FIBROLIPOMATOUS HAMARTOMA OF MEDIAN NERVE WITH MACRODYSTROPHIA LIPOMATOSA: MRI DIAGNOSIS

Usman Saeed,¹ Zahid Khan,² Bakhtiar Ahmad,¹ Ammar Ashraf¹

¹ King Abdulaziz Hospital for National Guards, Al-Ahsa, Saudi Arabia

² Royal Blackburn Hospital, East Lancashire Hospital NHS Trust, Blackburn, United Kingdom

PJR April - June 2014; 24(2): 68-70

ABSTRACT

Fibrolipomatous hamartoma of nerve is a rare benign disorder which most commonly involves the median nerve around wrist. Due to large size of median nerve, patient can present with symptoms of carpal tunnel syndrome. This entity has association with macrodystrophia lipomatosa. We report a case of fibrolipomatous hamartoma of median nerve and associated macrodystrophia lipomatosa. This patient presented with abnormal sensations in left hand which was enlarged, deformed and diagnosed on magnetic resonance imaging (MRI).

Introduction

Fibrolipomatous hamartoma of nerve is a rare benign tumor characterized by excessive fibrous and lipomatous tissue growth resulting in enlargement of epineurium and perineurium. This most commonly involves the median nerve around wrist and in distal forearm and less frequently can also affect radial, ulnar, sciatic and plantar nerve. Due to large size of median nerve, patient can present with symptoms of carpal tunnel syndrome. This entity has association with macrodystrophia lipomatosa. We report a case of fibrolipomatous hamartoma of median nerve and associated macrodystrophia lipomatosa. This patient presented with abnormal sensations in left hand which was enlarged and deformed.

Case Report

A 15-years old female patient presented for MRI of enlarged and deformed left hand. She had recently

developed pain and abnormal sensation in her hand and difficulty in performing routine daily tasks. There was a large non tender soft tissue mass on volar aspect of her hand extending into all four digits except little finger. She had enlarged and deformed index, middle finger and enlarged ring finger. This slow growing soft tissue mass and macrodactyly had been present since her birth. No edema or skin discoloration was present. She had history of multiple previous hand surgeries for cosmetic reasons leading to deformed index and middle fingers.

This was the only abnormality she has and there is no such family history.

We reviewed her x-rays of hand which showed generous amount of soft tissue involving the palm, thumb, index, middle and ring fingers. Distal metacarpals and phalanges of index and middle fingers had severe deformities and macrodactyly in ring finger.

MRI was performed acquiring Axial FSE T1, T2, sagittal FSE T2 and STIR sequences. This showed abundant fat in hand and gradual thickening of median

Correspondence : Dr. Usman Saeed
King Abdulaziz Hospital for
National Guards, Al-Ahsa,
Saudi Arabia
Email: drusaeed@gmail.com

Submitted 17 January 2015, Accepted 5 February 2015

nerve beyond mid forearm up to the wrist joint. Thickened nerve and its fascicles were hypointense on T1, T2 and STIR sequences with volar bowing of flexor retinaculum. Large amount of fat surrounding the nerve fascicles beyond flexor retinaculum took a mass like shape in the region of palm where they had characteristic coaxial cable like appearance on axial plane and spaghetti like appearance on coronal plane. Bony details were same as noted on plain x-rays. So the diagnosis of fibrolipomatous hamartoma of median nerve with macrodystrophia lipomatosa and carpal tunnel syndrome was confidently made.

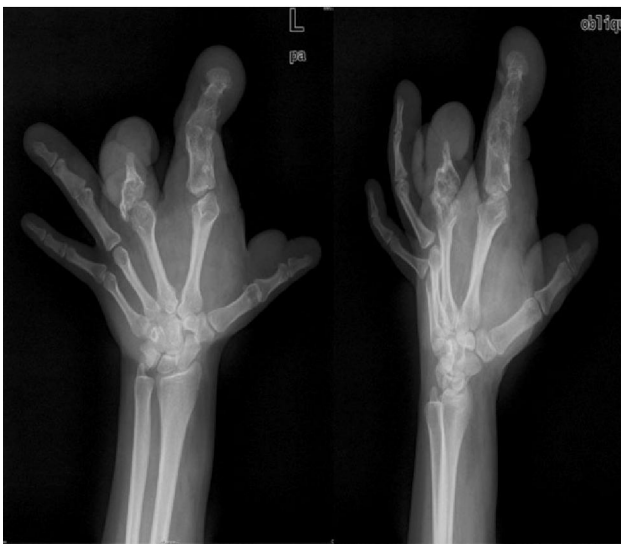

Figure 1: X-rays of left hand. Enlarged and deformed fingers and diffuse soft tissue swelling of hand. Evidence of previous surgery in middle finger.

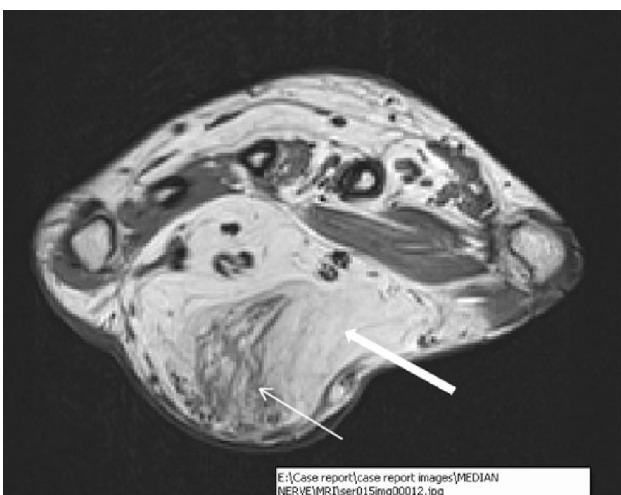


Figure 2: T1W axial image of left wrist joint. Large amount of fat (thick arrow) and spaghetti appearance (this arrow) of median nerve.

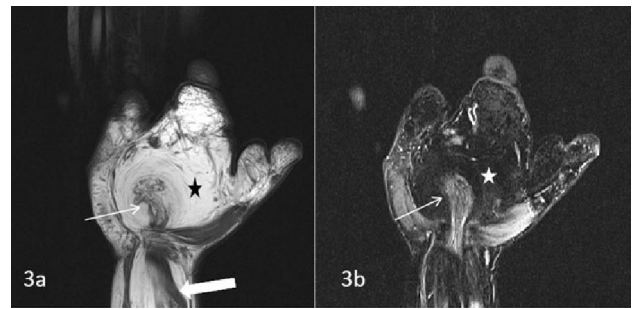


Figure 3a: Coronal T1W FSE. **3b:** T1 TIRM images of left wrist. Thickened median nerve (thick arrow) and its spaghetti appearance (thin arrows) with large amount of fat (black star in 3a and white star in 3b)

Discussion

Fibrolipomatous hamartoma of median nerve is a rare entity being first reported in 1953.¹ This is composed of fibrofatty over growth in and around epineurium and perineurium resulting in enlargement.² This usually targets patients younger than 30 years of age.³ Most commonly the hamartoma involves the median nerve and then in decreasing order of frequency this involves radial nerve, ulnar nerve, nerves at dorsum of foot, brachial plexus and cranial nerves.⁴ This most commonly is present at the level of wrist so presentation with carpal tunnel syndrome is fairly common. Proximal extent of nerve involvement is necessary for surgical planning.³

Etiology of fibrolipomatous hamartoma is not clear but since this occurs most commonly in younger population, this can be congenital⁵ however a few authors suggest its traumatic etiology.⁶

MRI in fibrolipomatous hamartoma of nerve has characteristic appearance i.e. coaxial cable like appearance on axial plane and spaghetti like appearance on coronal plane. This is so typical that this obviates the need of surgical biopsy.⁷

On ultrasound, this appears as a soft tissue mass with alternating hyper and hypoechoic bands on background of echogenic substratum reflecting MRI appearance.⁸

Differential diagnosis of this benign entity includes traumatic intraneural lipoma, ganglion cyst and vascular malformation where flow voids can mimic thick fascicles.^{3,8}

Macrodystrophia lipomatosa is associated finding in 22-67% of patients.² This is characterized by fibrofatty proliferation and macrodactyly in trajectory of median or plantar nerve of one or more digits. This process halts, for unknown reason, at puberty.⁹

Treatment options for this tumor with or without macrodystrophia lipomatosa are targeted for symptomatic relief by carpal tunnel release and cosmetic issues.² Dissection and microsurgical excision is not preferred first line surgical option since this carries high risk of permanent loss of motor and sensory function.³

References

1. Van Breuseghem I, Sciot R, Pans S et al. Fibrolipomatous Hamartoma in the foot: atypical MR imaging findings. *Skeletal Radiol* 2003; **32**: 651-5
2. Chia-Ling Chiang, Meng-Yuan Tsai, Clement Kuen-Huang Chen. MRI Diagnosis of Fibrolipomatous Hamartoma of the Median Nerve and Associated Macrodystrophia Lipomatosa. *Chin Med Assoc* 2010; **73(9)**: 499-502
3. Jamal Louaste, Hassan Zejjari, Mohamed Chkoura et al. Carpal tunnel syndrome due to fibrolipomatous hamartoma of the median nerve. *HAND* 2011; **6**: 76-9.
4. Ly JQ, Bui-Mansfield LT, SanDiego Jw et al. Neural fibrolipoma of the foot. *J Comput Assist Tomogr*. 2003; **27**: 639-40
5. Silverman TA, Enzinger FM: Fibrolipomatous hamartoma of nerve. A clinicopathologic analysis of 26 cases. *Am J Surg Pathol* 1985, **9**: 7-14.
6. De Maeseneer M, Jaovisidha S, Lenchik L, Witte D, Schweitzer ME, Sartoris DJ, Resnick D: Fibrolipomatous hamartoma: MR imaging findings. *Skeletal Radiol* 1997; **26**: 155-60.
7. Toms AP, Anastakis D, Bleakney RR et al. Lipofibromatous hamartoma of the upper extremity: a review of the radiologic findings for 15 patients. *AJR Am J Roentgenol* 2006; **186**: 805-11.
8. TP Jain, DN Srivastava, R Mittal et al. Fibrolipomatous Hamartoma of median nerve. *Australasian Radiology* 2007; **51**: 98-100.
9. Brodwater BK, Major NM, Goldner RD et al. Macrodystrophia lipomatosa with associated fibrolipomatous hamartoma of the median nerve. *Pediatr Surg Int* 2000; **16**: 216-8.