

ABDOMINAL COCOON: TWO CASE REPORTS

Samina Akhtar, Rashed Nazir, Ahson Ahmed

Department of Radiology, Shifa International Hospital, Islamabad, Pakistan.

PJR April - June 2014; 24(2): 64-67

ABSTRACT

Abdominal cocoon is a rare cause of bowel obstruction. We present two cases with symptoms of bowel obstruction. Both were diagnosed on post contrast CT and findings were confirmed on laparotomy and histopathology. Clinical presentation, CT imaging features and pathological correlation are discussed.

Introduction

Abdominal cocoon, also known as idiopathic sclerosing encapsulating peritonitis, is a rare entity usually presenting in adults with symptoms of bowel obstruction. It can be easily diagnosed on contrast enhanced CT and the only treatment option for it, is laparotomy with adhesiolysis. We present two cases of abdominal cocoon came to our hospital in the past two years. The CT features, per-operative findings and pathological correlation are discussed below.

Case Reports

Case 1: A 26-year-old male presented in the ER with generalized abdominal pain and distention for 6 hrs associated with nausea, two episodes of vomiting and constipation. He had similar episode of abdominal pain 5 months ago which was treated conservatively. He had no past history of surgery or tuberculosis. On examination the abdomen was distended and tender all over with sluggish bowel sounds. His abdominal radiographs showed non-specific bowel gas shadows. Postcontrast CT abdomen was performed which showed encasement of entire small bowel. The jejunal

and ileal loops, from DJ flexure till ileocecal junction, were wrapped in a thick smooth fibrous membrane. The small bowel was arranged in a concertina pattern giving a cauliflower appearance. The sigmoid colon was also encapsulated by similar inferior extension of this fibrous membrane. There was small amount of free interloop fluid. There was no twist in the mesentery. SMV and SMA were in normal location. Entire small and large bowel showed normal post contrast enhancement and no signs of bowel ischemia were observed.

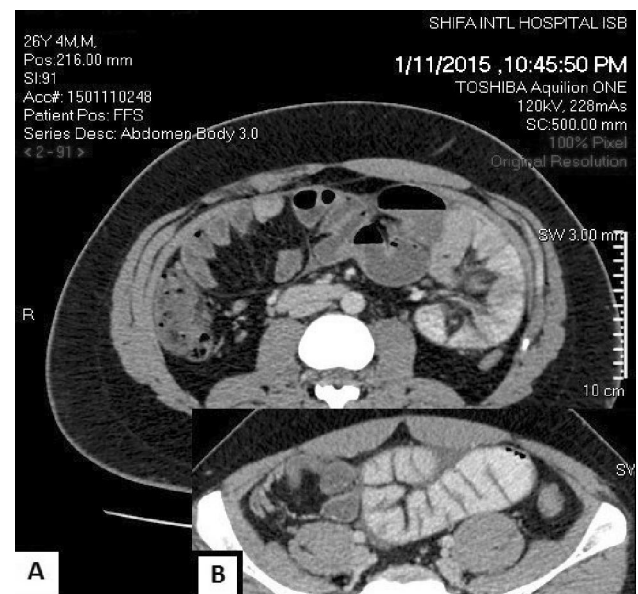


Figure 1A and B: Case 1: Small bowel loops arranged in concertina pattern surrounded by a fibrous membrane.

Correspondence : Dr. Samina Akhtar
Department of Radiology,
Shifa International Hospital,
Islamabad, Pakistan.
Email: saminaakhtar2000@yahoo.co.uk

Submitted 11 February 2015, Accepted 26 February 2015

Exploratory laparotomy was performed immediately after the CT diagnosis. Intraoperatively there was thick smooth shiny membrane covering the small bowel and sigmoid colon. The membrane was split open to release the small bowel as well as the sigmoid colon. The mesentery was explored and prominent hard lymph nodes were found in the sigmoid mesentery. The membrane and lymph nodes were taken out for histopathology. Histopathology of the membranes showed fibrocollagenous tissue and the lymph nodes showed fat necrosis. There were no granulomas and the biopsy sample was negative for malignancy. The patient had uneventful recovery and remained well thereafter.

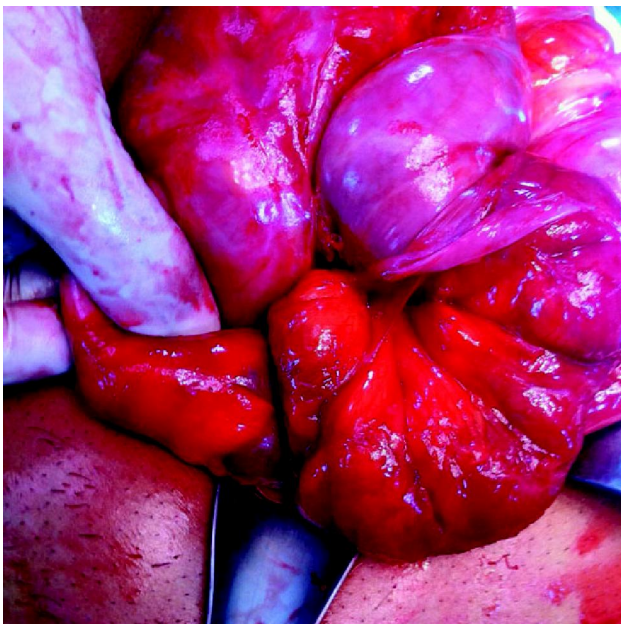

Figure 2: Case 1: Intra-operative image of small bowel covered with smooth shiny fibrous sheath and some segment of uncovered bowel after splitting open the abdominal cocoon.

Case 2: A 60-year-old male presented in OPD with symptoms of decreased appetite and multiple episodes of vomiting for 2 months. On examination there was a palpable mass in the epigastrium and LUQ. He had past history of appendectomy 3 years prior to presentation. Abdominal radiograph showed non-specific bowel gas shadows without any signs of obstruction.

Contrast enhanced CT showed encasement of the entire small bowel, from DJ flexure till ileum, in a thick enhancing membrane with small amount of loculated

fluid. The small bowel loops were contrast distended. On laparotomy bowel was encased by thick fibrous mantle starting from DJ flexure to sigmoid colon with dense adhesions. Abdominal cocoon was excised and bowel was release with adhesiolysis. The membranes were taken out and sent for histopathology which showed fibrocollagenous and fibroadipose tissue with congested vessels and mild chronic nonspecific inflammation. The sample was negative for granuloma and malignancy. The patient remained well after that without recurrence.

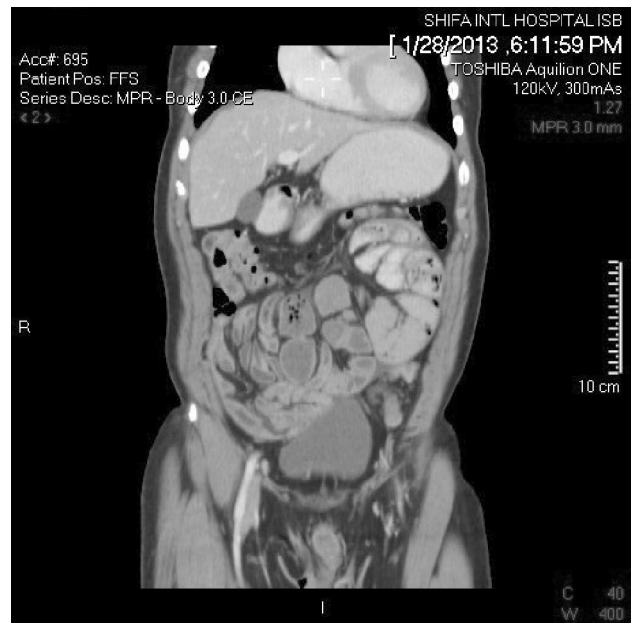

Figure 3: Case 2: Small bowel loops wrapped in a thick membranous sac present obliquely in the center of abdomen.

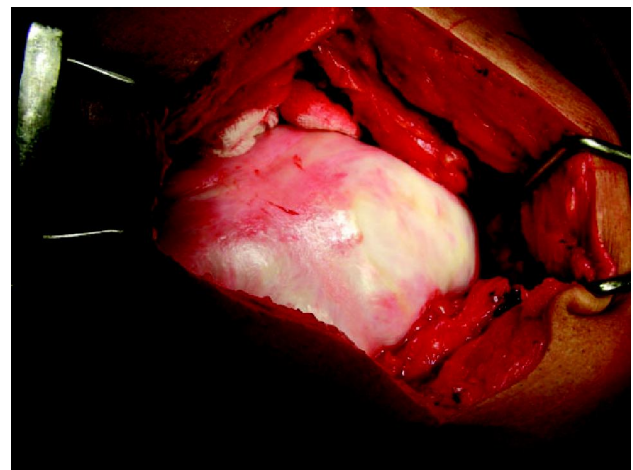


Figure 4: Case 2: Intra-operative appearance of abdominal cocoon covered with smooth shiny white fibrous sheath.

Discussion

Idiopathic sclerosing encapsulating peritonitis is a rare condition which usually presents in adults. We came across two patients of different age groups. Patients present with recurrent symptoms of bowel obstruction. Our younger patient presented with acute symptoms lasting for 6 hours while the older patient had a chronic history for 2 months.

There are multiple causes of abdominal cocoon. Most common of these are peritoneal dialysis, ventriculo-peritoneal shunt, sarcoidosis, SLE, peri-toneal tuberculosis, recurrent peritonitis, beta blocker i.e. practolol and prior history of surgery. It can be congenital as well in which the bowel is encased by accessory peritoneal membrane.⁵ Pathologically this membrane is normal peritoneum rather than fibro-collagenous membrane found in idiopathic sclerosing encapsulating peritonitis.⁶ Early cases of abdominal cocoon were diagnosed in females and retrograde menstruation was considered to be the etiology.¹ In our two cases the exact etiology of abdominal cocoon was uncertain in however one patient had a prior history of appendectomy.

Imaging is necessary to make the diagnosis of abdominal cocoon. Literature review has shown that ultrasound can help diagnose this condition however excessive bowel gases can limit the details of bowel.⁴ CT is the best cross sectional imaging modality for diagnosing this entity. Preoperative diagnosis on CT is challenging and is usually confused with internal abdominal hernia. Our both cases were diagnosed on contrast enhanced CT. Both cases had characteristic imaging features of abdominal cocoon.

On CT abdominal cocoon appear as conglomerates of small bowel loops encased in a sac. The small bowel is partially or completely arranged in concertina pattern in thick smooth fibrous membrane giving cauliflower appearance.² It can lead to small bowel obstruction and bowel ischemia if remained untreated. Post contrast CT can further help in diagnosing concurrent bowel ischemia secondary to entrapment and strangulation by these membranes.⁸ Although rare it should be considered a cause of bowel obstruction especially when the patient comes with


recurrent episodes of abdominal pain and vomiting. The only treatment option for abdominal cocoon is laparotomy with resection of membrane and release of entrapped bowel.^{3,7} Resection of bowel is usually done when the bowel has strangulated. Our both patients were treated surgically by exploratory laparotomy with dissection and removal of encapsulating membrane. Both patients showed good post-operative response. Although abdominal cocoon is a rare entity, this should be suspected clinically especially when patient presents with recurrent signs and symptoms of bowel obstruction.

Conclusion

Abdominal cocoon is a rare entity usually presenting with recurrent episodes of bowel obstruction. CT is the modality of choice for pre-operative diagnosis of this condition which in turn helps surgeons in treating it surgically by dissection, removal of membranes and releasing the encased bowel. Long term prognosis of this condition is good without recurrence.

References

1. Foo KT, Ng KC, Rauff A, Foong WC, Sinniah R. Unusual small intestinal obstruction in adolescent girls: the abdominal cocoon. *Br J Surg* 1978; **65(6)**: 427-30.
2. Hur J, Kim KW, Park MS, Yu JS. Abdominal cocoon: preoperative diagnostic clues from radiologic imaging with pathologic correlation. *AJR Am J Roentgenol* 2004; **182**: 639-41.
3. Kirshtein B, Mizrahi S, Sineelnikov I, Lantsberg L. Abdominal cocoon as a rare cause of small bowel obstruction in an elderly man: Report of a case and review of literature. *Indian J Surg* 2011; **73(1)**: 73-5.
4. Vijayaraghavan SB, Palanivelu C, Sendhilkumar K, Parthasarathi R. Abdominal cocoon: Sonographic features. *J Ultrasound Med* 2003; **22**: 719-21.

-
- 
5. Devay AO, Gomceli I, Korukluoglu B, Kusdemir A. An unusual and difficult diagnosis of intestinal obstruction: The abdominal cocoon. Case report and review of the literature. *World J Emerg Surg* 2008; **3**: 36.
 6. Casas JD, Mariscal A, Martinez N. Peritoneal encapsulation: CT appearance. *AJR Am J Roentgenol.* 1998; **171**: 1017-9.
 7. Wei B, Wei HB, Guo WP, Zheng ZH, Huang Y, Hu BG, et al. Diagnosis and treatment of abdominal cocoon: a report of 24 cases. *Am J Surg* 2009; **198**: 348-53.
 8. Gupta RK, Chandra AS, Bajracharya A, Sah PL. Idiopathic sclerosing encapsulating peritonitis in an adult male with intermittent subacute bowel obstruction, preoperative multidetector-row CT (MDCT) diagnosis. *BMJ Case Rep.* 2011; **10**: 1136.