

VISUAL AND OTOLOGICAL MANIFESTATION OF CAMURATI-ENGELMANN'S DISEASE: A CASE REPORT

Tariq Alam,¹ Muhammad Khurram Munir,² Yasir Jamil Khattak,³ Asif Alam Khan⁴

¹ French medical Institute Kabul, Afghanistan.

² Department of Radiology, The Aga Khan University Hospital, Karachi, Pakistan.

³ North West General Hospital & Research Center, Karachi, Pakistan.

⁴ Khyber Medical college, Peshawar, KPK, Pakistan.

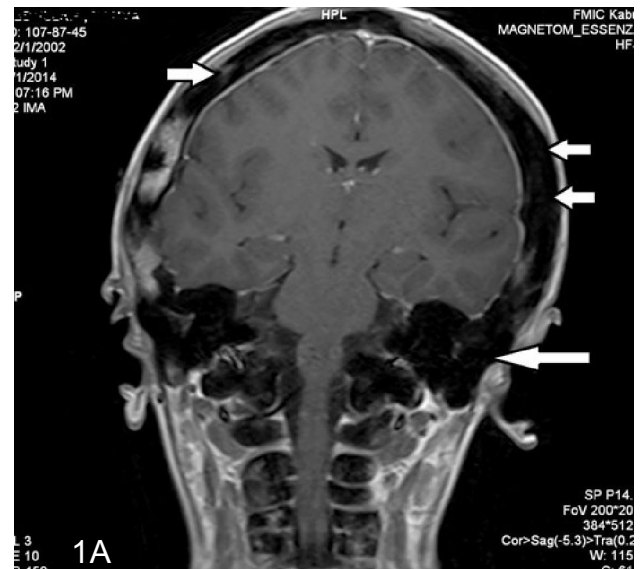PJR April - June 2016; 26(2): 140-143

ABSTRACT

Camurati Engelmann's disease (CED) is a rare disorder worldwide with just over 200 cases reported. No case of CED has been reported in Afghanistan till date. It has been previously reported that domain specific mutations in transforming growth factor (TGF)- β 1 gene on chromosome 19q13.1 have been reported to cause this disorder.¹⁻³ Its pattern of inheritance is autosomal dominant with variable penetrance.⁴ Most patients of CED (also known as progressive diaphyseal dysplasia (PDD), oosteopathica hyperostotica multiplex infantilis) present with extremity pain, muscle weakness and waddling gait. Symptomatology relating to cranial nerve impingement is secondary to amorphous increase in the density of skull bones resulting in stenosis of various foramina/spaces within skull. It tends to be bilateral and symmetrical and can affect any bone but has greater affinity for long bones e.g. humerus, femur, tibia, ulna and radius. Other common sites include skull and pelvis.^{5,6}

Case Presentation

A 9 year old boy presented to his clinician with a history of gradual loss of hearing and vision in both eyes over the preceding 7 months. He was also complaining of pain localized to his calf and thigh muscles. There was no history of joint swelling. He had been previously well with no relevant past medical history. Clinical examination revealed the child to be pale, lethargic and having a waddling gait. Based on the clinical history his clinician referred him for MRI of the brain to exclude any space occupying lesion which may be the cause of his hearing and visual loss. His MRI revealed marked hyperostosis of the skull vault bones as well as the base of skull which is appearing hypointense on T2 weighted images (Fig 1). Marked narrowing of bilateral optic nerve



Correspondence : Dr. Asif Alam Khan
Khyber Medical College
Peshawar, KPK, Pakistan.
Email: aak_doc@yahoo.com

Submitted 28 July 2015, Accepted 15 August 2015

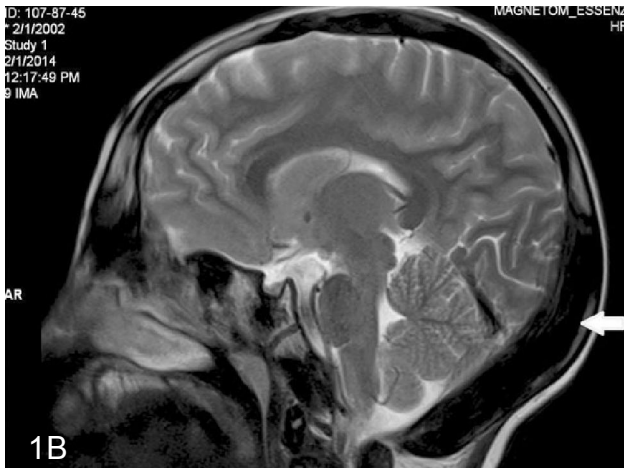

Figure 1: T1 weighted Coronal Post contrast (1a) and T2 Weighted midline sagittal (1b) images. The bones of base of skull and vault appear significantly thickened and hypointense (Arrows), representing marked hyperostosis.

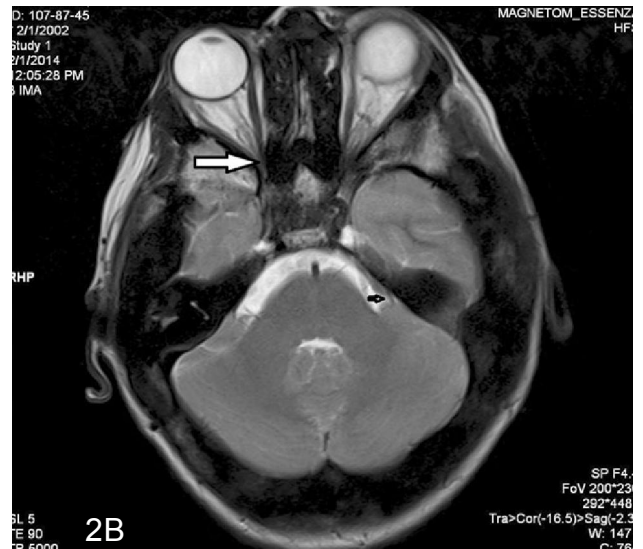
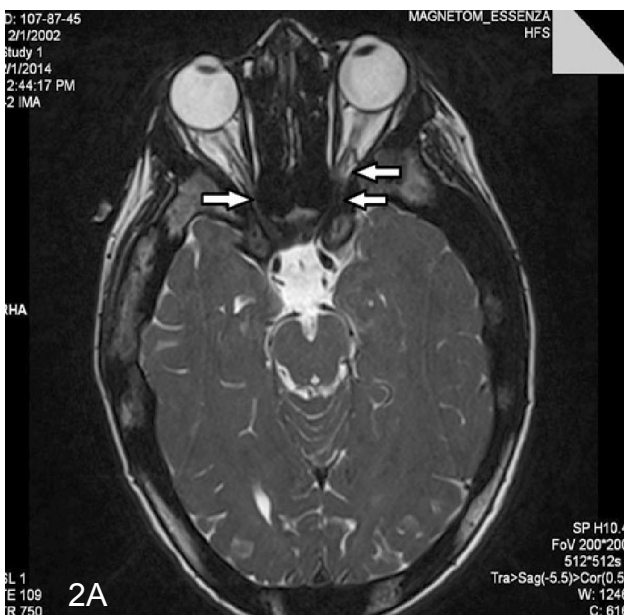


Figure 2: T2 Weighted axial image at the level of optic canals showing marked narrowing of bilateral optic nerve canals due to hyperostosis (Arrows). The optic nerves can be seen compressed in the region of bilateral optic canals

canals due to hyperostosis was noted. The optic nerves were compressed in the optic canals (Fig 2). Sclerosis is also seen in the region of petrous part of temporal bone which may be the reason for hearing loss. Sclerosis of the visualized upper cervical vertebrae was also seen. Findings were suggestive of Camurati-Engelmann's disease. After discussion with the primary physician radiograph of left femur was performed which revealed diffuse diaphyseal hyperostosis (Fig 3).

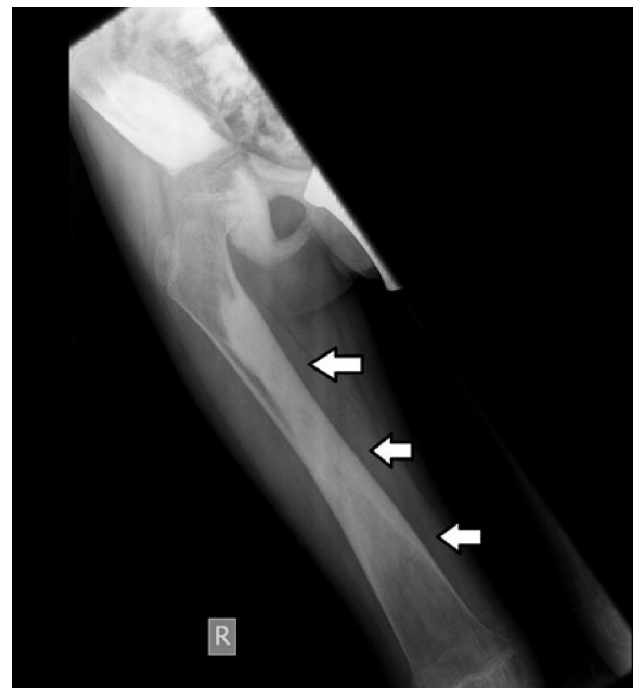

Figure 3: Radiograph of left femur showing diffuse diaphyseal hyperostosis



Discussion

Medical treatment of bony abnormalities with glucocorticoids (prednisolone) has been tried with success in patients of CED^{7,8} but failure of treatment with bisphosphonates have also been reported.⁹

Moumoulidis et al described otological manifestation in CED as a result of narrowing of internal auditory canals caused by bony encroachment on nerves and vessels.¹⁰ This results in retrocochlear hearing loss, meanwhile, the narrowing of tympanic cavities and Eustachian tube may precipitate middle ear infections and/or adhesions of ossicles to the tympanic walls.¹¹ The incidence of hearing impairment in the patients of CED is estimated to be about 18%.¹² Cochlear implantation for auditory rehabilitation in patients of CED has been described by Friedland et al¹¹ and Tibesar.¹³ Surgical decompression of internal auditory meatus to relieve vertigo in case of CED has also been successfully done.¹⁴

Visual manifestation of CED can be considered as a late sequelae of disease process. Wright M reported that visual symptoms may take some time to develop.¹⁵ Initial symptom may only be of exophthalmos or headache due to raised intracranial pressure (ICP) and a decrease in visual acuity may be the presentation later in the disease process.¹⁵ It may well be the chief presenting symptoms as with this case.

Visual symptoms are not limited to CED alone, other conditions of primary bone disorders such as cranio-metaphyseal dysplasia, osteopetrosis and aneurysmal bone cyst, all of which have been reported to cause progressive stenosis of optic canals.¹⁶⁻¹⁸ The etiology of visual symptoms in some case have been presumed to have occurred solely due to compressive optic neuropathy^{19,20} however, symptoms can also be due to papilloedema secondary to raised intracranial pressure.¹⁵

In our case visual symptoms were due to marked narrowing of bilateral optic nerve canal due to hyperostosis. The optic nerves can be seen compressed in the region of bilateral optic canals (Fig 2). Treatment rationale will be different as papilloedema has been treated with diuretics (acetazolamide)¹⁵ and surgical decompression reported as the best management in cases of compressive optic neuropathy. However, in some cases and overlap of both mechanisms may be encountered. It is suggested that some type of cranial vault expansion procedure, possibly combined with an orbital decompression may be beneficial as well.¹⁵ Here it should be kept in mind that, surgery may not be curative and reconstitution of surgically resected bone may be encountered.^{19,21}

Conclusion

In conclusion, the report describes the first case ever of CED to be reported out of this region of the world and it's presenting symptomatology.

References

1. Kinoshita A, Saito T, Tomita H-a, Makita Y, Yoshida K, Ghadami M, et al. Domain-specific mutations in TGF β 1 result in Camurati-Engelmann disease. *Nature genetics*. 2000; **26(1)**: 19-20.
2. Simsek S, Janssens K, Kwee ML, Van Hul W, Veenstra J, Netelenbos JC. Camurati Engelmann disease (progressive diaphyseal dysplasia) in a Moroccan family. *Osteoporosis international*. 2005; **16(9)**: 1167-70.
3. Wu S, Liang S, Yan Y, Wang Y, Li F, Deng Y, et al. A novel mutation of TGF β 1 in a Chinese family with Camurati Engelmann disease. *Bone*. 2007; **40(6)**: 1630-4.
4. Hundley JD, Wilson FC. Progressive diaphyseal dysplasia Review of the literature and report of seven cases in one family. *The Journal of Bone & Joint Surgery*. 1973; **55(3)**: 461-74.
5. Camurati M. Di un raro caso di osteite simmetrica ereditaria degli arti inferiori. *Chir Organi Mov*. 1922; **6**: 662-5.
6. Engelmann G. Ein Fall von Osteopathia hyperostotica (sclerotisans) multiplex infantilis. *Fortschr Roentgenstr*. 1929; **39**: 1101-6.
7. Heymans O, Gebhart M, Alexiou J, Sokolow Y. Camurati-Engelmann disease. Effects of corticosteroids. *Acta clinica Belgica*. 1998; **53(3)**: 189-92.
8. Inaoka T, Shuke N, Sato J, Ishikawa Y, Takahashi K, Aburano T, et al. Scintigraphic evaluation of pamidronate and corticosteroid therapy in a patient with progressive diaphyseal dysplasia (Camurati-Engelmann disease). *Clinical nuclear medicine*. 2001; **26(8)**: 680-2.

9. Castro GRW, Appenzeller S, Marques-Neto JoF, BÃ©rtolo MB, Samara AM, Coimbra I. Camurati-Engelmann disease: failure of response to bisphosphonates: report of two cases. *Clinical rheumatology*. 2005; **24(4)**: 398-401.
10. Moumoulidis I, De R, Ramsden R, Moffat D. Unusual otological manifestations in Camurati-Engelmann's disease. *The Journal of Laryngology & Otology*. 2006; **120(10)**: 892-5.
11. Friedland DR, Wackym PA, Rhee JS, Finn MS. Cochlear implantation for auditory rehabilitation in Camurati-Engelmann disease. *The Annals of otology, rhinology, and laryngology*. 2000; **109(2)**: 160-2.
12. Higashi K, Matsuki C. Hearing impairment in Engelmann disease. *Otology & Neurotology*. 1996; **17(1)**: 26-9.
13. Tibesar RJ, Brissett AE, Shallop JK, Driscoll CLW. Internal auditory canal decompression and cochlear implantation in Camurati-Engelmann disease. *Otolaryngology-Head and Neck Surgery*. 2004; **131(6)**: 1004-6.
14. Hellier WPL, Brookes GB. Vestibular nerve dysfunction and decompression in Engelmann's disease. *Journal of laryngology and otology*. 1996; **110**: 462-5.
15. Wright M, Miller NR, McFadzean RM, Riordan-Eva P, Lee AG, Sanders MD, et al. Papilloedema, a complication of progressive diaphyseal dysplasia: a series of three case reports. *British journal of ophthalmology*. 1998; **82(9)**: 1042-8.
16. Puliafito CA, Wray SH, Murray JE, Boger 3rd WP. Optic atrophy and visual loss in craniometaphyseal dysplasia. *American journal of ophthalmology*. 1981; **92(5)**: 696-701.
17. Aasved H. Osteopetrosis from the ophthalmological point of view. A report of two cases. *Acta ophthalmologica*. 1969; **48(4)**: 771-8.
18. Calderon M, Brady HR. Fibrous dysplasia of bone with bilateral optic foramina involvement. *American journal of ophthalmology*. 1969; **68(3)**: 513-5.
19. Yen JK, Bourke RS, Popp AJ, Wirth CR. Camurati-Engelmann disease (progressive hereditary craniodiaphyseal dysplasia) Case report. *Journal of neurosurgery*. 1978; **48(1)**: 138-42.
20. Walsh FB, Hoyt WF. *Clinical neuro-ophthalmology*. 3d ed. Baltimore,: Williams & Wilkins; 1969.
21. Krohel GB, Wirth CR. Engelmann's disease. *American journal of ophthalmology*. 1977; **84(4)**: 520-5.