

DIAGNOSTIC ACCURACY OF SPECTRAL DOPPLER ULTRASOUND IN DIFFERENTIATING BETWEEN BENIGN AND MALIGNANT SOLID BREAST LESIONS TAKING HISTOPATHOLOGY AS GOLD STANDARD

Bushra Arshad, Mahjabeen Mahmood Kamal, Muhammad Wasim Awan, Shaghaf Iqbal, Syed Naveed Ali Shah, Wajiha Arshad, Nasreen Rehmatullah

Department of Radiology, KRL Hospital, Islamabad, Pakistan.

PJR October - December 2022; 32(4): 175-180

ABSTRACT

OBJECTIVE: To determine the diagnostic accuracy of spectral Doppler ultrasound in predicting malignancy in evaluation of solid breast lesions taking histopathology as gold standard. **MATERIALS AND METHODS:** This cross sectional validation study was conducted at Radiology department, KRL Hospital, Islamabad for six months from 1st August 2021 to 31st January 2022. A total of 145 women with solid breast lesions of BI-RADS category scale III-V were included in the study. All women underwent spectral Doppler ultrasound of breast and malignancy was considered positive if spectral Doppler US image shows resistive index (RI)= 0.68. These patients were then subjected to histopathology. The data was collected on a predesigned proforma and results were analyzed by using the SPSS software version 17.0 by descriptive and inferential statistics. **RESULTS:** In this study age range was 18 to 60 years with mean age of 42.965 – 7.66 years. Spectral Doppler ultrasound has shown sensitivity of 84.8%, specificity 95% and diagnostic accuracy by 92%, PPV 88.6% and NPV 93% in diagnosis of malignant breast lesion. **CONCLUSION:** In conclusion, Doppler examination has a significant role in the evaluation of solid breast lesions for distinguishing malignant tumors from benign lesions.

Keywords: Solid breast lesions, Spectral doppler ultrasound, Histopathology, Diagnostic accuracy

Introduction

According to the American Cancer Society, about 1.3 million women around the world are diagnosed with breast cancer every year and 465,000 die from the disease.¹ Breast cancer, the most common malignancy in the women's population, is the second most common cause of cancer related mortality in this group and the leading cause of mortality among women aged 45-55 years.² These statistics emphasize the necessity of screening and early diagnosis of breast cancer.³ Nowadays, sonography is one of the main methods for diagnosing breast diseases and is used to detect and evaluate breast lesions.⁴

The criteria for differentiating between benign and malignant lesions from gray scale sonography are widely known.⁵ Although tumor vascularity is becoming highly important in prognostic, diagnostic, and possible therapeutic terms, there have always been controversies in different studies to define acceptable criteria for differentiating benign and malignant breast lesions by Doppler sonography (DS).⁶ Some studies have even doubted its usefulness.⁷⁻⁸ Although mammography is recognized as the best screening method for breast cancer, combining mammography and ultrasonography (US) helps to improve detection,

Correspondence : Dr. Bushra Arshad
Department of Radiology,
KRL Hospital,
Islamabad, Pakistan.
Email: bushraarshad129@gmail.com

Submitted 4 October 2022, Accepted 26 October 2022

especially if the woman has dense breasts.⁸ Furthermore, the detected breast lesions can be characterized more accurately when these modalities are used in combination than on their own. The association between angiogenesis (i.e. the formation of new blood vessels) and cancer was first described by Folkman in 1971.⁹ Metabolically active cancer cells demand more oxygen and nutrients than normal vessels are able to provide, resulting in hypoxia. This hypoxic state stimulates the formation of new vessels that run from existing blood vessels into the tumor in order to maintain the tumor's metabolic homeostasis. Doppler ultrasound (including color and spectral methods) can help to differentiate benign masses from malignant tumors. This technique may obviate the need for biopsy in some suspicious lesions.

Color Doppler can recognize neo-vascularization, which may be used as a clue for detecting malignant lesions.¹⁰ The findings of color Doppler studies however may be overlapped in highly vascular benign masses and malignant neoplasms.¹¹ This overlap makes it difficult to differentiate malignant tumors from benign masses just based on color Doppler features. However, it seems that the combination of spectral and color Doppler study may increase the sensitivity and specificity of ultrasound examination for detecting breast masses with high probability of malignancy. In addition, awareness of the vascularity status of the lesion is valuable for making decision upon performing neoadjuvant chemotherapy and monitoring response to the treatment.¹²

Currently, spectral Doppler parameters are not considered in many imaging centers as a part of routine breast ultrasound examination in the daily practice. Ultrasound is a safe, non-invasive and radiation free adjunct to mammography for the evaluation of breast masses. It is also used as a primary screening tool for breast cancer in women who are pregnant, young women with high risk for breast cancer and who have increased breast density on mammogram. If results come in favor of Spectral doppler ultrasound it may help to prevent some unnecessary biopsies, and also can guide the treatment strategies in the future.

Material and Methods

145 women fulfilling the inclusion criteria from Radiology department, KRL Hospital, Islamabad

were included in the study after permission from ethical committee. Informed consent was taken from all patients explaining benefits of study. Patients with breast lesions having suspected malignancies falling under the category III, IV and V were included in the study, however patients with known malignancies, post biopsy, on hormone replacement therapy, or taking treatment for breast malignancies, pregnant ladies and those having cystic components were not included in the study. The breast ultrasound may yield limited information in patients with ulcerated lesions or in obese patients. Basic demographics like age and duration of complaint were noted.

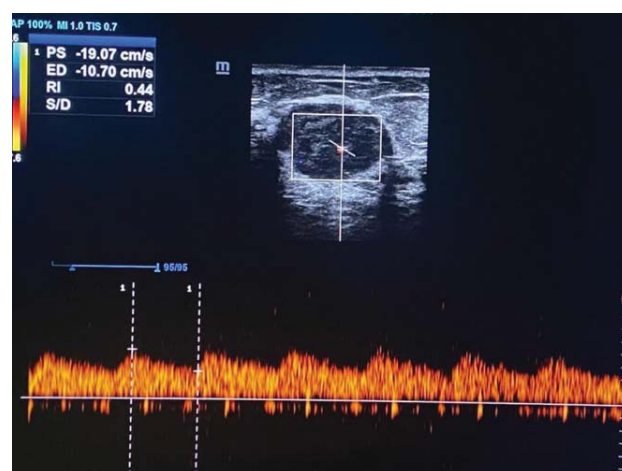


Figure 1: Doppler ultrasound of breast lesion showing RI value of 0.4 suggesting a malignant looking lesion.

All women underwent spectral doppler ultrasound of breast and malignancy was considered positive if spectral doppler US image shows resistive index (RI)= 0.68 as per operational definition. In (Fig.1), we can see a lesion with RI values 0.4 on spectral Doppler suggesting low resistance and in turn representing a malignant looking lesion, while in (Fig.2) we can see a lesion with RI values 0.7 on spectral Doppler, suggesting high resistance to vascular flow and in turn a benign looking lesion. Ultrasound examination was conducted under the supervision of a consultant radiologist of three years post fellowship experience on a logic P/6 3D machine.

All of the lesions were followed by biopsy with 18 G Trucut needle. Three cores were obtained and fixed in formalin. The labeled specimen were examined and reported by a consultant histopathologist of three years post fellowship experience. Positive biopsy

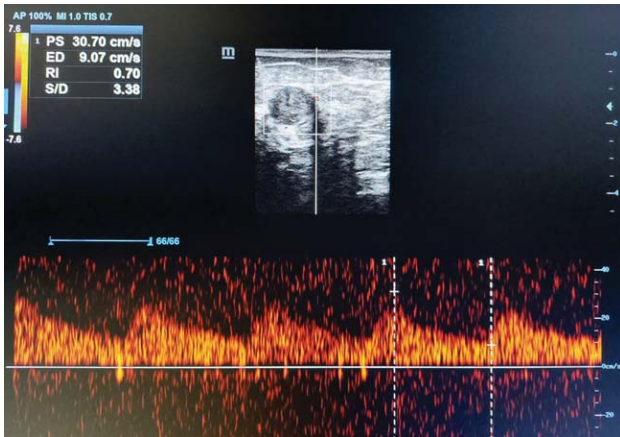


Figure 2: Doppler ultrasound of a breast lesion showing RI values of 0.7 suggesting a benign looking lesion.

specimen showed (all of following) distended duct with intact basement membrane, micropapillary and cribriform growth pattern. All the data regarding findings of spectral Doppler ultrasound and histopathology was noted by researcher herself on specially designed proforma (Annexure-I). The patients undergoing surgery or neoadjuvant chemotherapy for the lesion, pregnant women, and the ones showing cystic and fluid filled breasts lesions were not included in the study. Data was entered and analyzed by SPSS software version 17.0 by descriptive and inferential statistics. Mean – standard deviation was calculated for all quantitative variables like age and duration of complain. Frequency and percentage was calculated for qualitative variables like age groups and BI-RADS category scale. Sensitivity, specificity, positive predictive value, negative predictive value and diagnostic accuracy for spectral doppler ultrasound against histopathology was calculated by using 2 x 2 model.

Results

In this study age range was 18 to 60 years with mean age of 42.965 – 7.66 years and mean duration of complain was 4.937 – 2.03 months.

Frequency and percentage of patients according to age group showing 33.8 percent in the age range of 18 to 41 and 66.2 in the age 41 to 60 years. BI-RADS category scale are shown in (Tab.1).

Spectral Doppler ultrasound diagnosed 44 (30.3%) patients while histopathology diagnosed 46 (31.7%)

patients with malignant breast lesion as shown in (Tab.2).

Spectral Doppler ultrasound has shown sensitivity of 84.8%, specificity 95% and diagnostic accuracy by 92%, PPV 88.6% and NPV 93% in diagnosis of malignant breast lesions. Stratification with respect to age and BIRAD Category scale of spectral Doppler versus histopathology is shown in (Tab.3, 4 and 5).

BI-RADS category scale	No. of patients	%age
III	81	55.9%
IV	39	26.9%
V	25	17.2%
Total	145	100%

Table 1: Percentage and frequency of patients according to BI-RADS Category Scale n=145

Malignant breast lesion	Spectral Doppler Ultrasound	Histopathology
Present	44 (30.3%)	46 (31.7%)
Absent	101 (69.7%)	99 (68.3%)
Total	145 (100%)	145 (100%)

Table 2: Overall results of spectral Doppler ultrasound and histopathology in diagnosis of malignant breast lesion n=145

Spectral Doppler Ultrasound	Histopathology		Total
	Present	Absent	
Positive	39 (TP)	5 (FP)	44
Negative	7 (FN)	94 (TN)	101
Total	46	99	145

Chi square = 94.46
P value = 0.000

Table 3: Comparison of spectral Doppler ultrasound versus histopathology for diagnosis of malignant breast lesion n=145

Spectral Doppler Ultrasound	Histopathology		Total	P value
	Present	Absent		
Positive	3 (TP)	1 (FP)	4	0.000
Negative	0 (FN)	45 (TN)	45	
Total	3	46	49	

Sensitivity = 100%
Specificity = 97.8%
DA = 98%
PPV = 75%
NPV = 100%

Table 4: Stratification with respect to age (18-40 years) of spectral Doppler ultrasound versus histopathology n=49

Spectral Doppler Ultrasound	Histopathology		Total	P value
	Present	Absent		
Positive	36 (TP)	4 (FP)	40	0.000
Negative	7 (FN)	49 (TN)	56	
Total	43	53	96	

Sensitivity = 83.7%
 Specificity = 92.4%
 DA = 89%
 PPV = 90%
 NPV = 87.5%

Table 5: Stratification with respect to age (41-60 years) of spectral Doppler ultrasound versus histopathology n=96

Results

In our study, spectral Doppler ultrasound has shown sensitivity of 84.8%, specificity 95% and diagnostic accuracy by 92%, PPV 88.6% and NPV 93% in diagnosis of malignant breast lesion. In a study by Keshavarz E, et al. has shown that spectral Doppler ultrasound had sensitivity of 85% and specificity of 74% for differentiating between benign and malignant solid breast lesions, with a prevalence of malignant lesions by 35% confirmed on histopathology.¹³ In the present study, the comparison of malignant and benign lesions revealed that malignant tumors were much larger. In addition, the main characteristics of malignant tumors included un-circumscribed margin, solid-cystic component, and mixed echogenicity. These findings are consistent with previous studies.¹⁴⁻¹⁷ Color Doppler helps to detect neovascularization in malignant tumors and may help to distinguish them from benign breast masses.¹⁸⁻²³ In the present study, hypervascularity and detectable flow were more common in the malignant lesions. Similarly, in a study conducted by Grischke et al. central blood flow was detectable in 71% and 6.6% of malignant and benign breast masses, respectively.²¹ The positive predictive value (PPV) for malignancy detection based on the combination of breast B-mode ultrasound findings and color Doppler patterns was reported 92%.²² A lesion vascularization status can be an indicator of malignant potential, metastasis potential, and invasiveness. Moreover, it may provide information about response to treatment and prog-

nosis. Lee et al. studied 52 malignant tumors and 32 benign breast lesions, and found that the presence of high-flow in the early stages of breast tumor is associated with the higher probability of metastasis to the axillary lymph-nodes.⁵ It was classically thought that malignant breast tumors have stronger color Doppler signals compared to benign lesions. However, subsequent studies showed that this is not always true. In general, vascularization is increased in high grade high-cellular malignant tumors, which have special feeding vessels helping them grow and invade, while low grade malignant tumors may have no detectable vascularity on color Doppler examination.^{17,24} On the other hand, some studies have reported that there is an overlap in color Doppler findings of hypervascular benign masses and malignant tumors.²³ This is not unusual, and makes it difficult to differentiate malignant tumors from benign lesions just based on color Doppler pattern. However, it seems that the combination of B-mode ultrasound and color Doppler findings can increase the sensitivity and specificity of ultrasound examination for determining the nature of breast tumors. In this study, the mean values of PSV, RI, and PI were significantly higher in malignant tumors compared to benign lesions. In addition, all of these indices, particularly PI, had high sensitivity and specificity for differentiating malignancies from benign lesions. The findings of this study are similar to some previous studies. For example, Chao et al. reported that PSV, RI, and PI are higher in carcinomas; however, unlike our investigation, they did not find any cut-off point to distinct benign and malignant tumors according to these characteristics.¹⁶ Studying on 70 breast masses, Stanzani et al. demonstrated that $RI \geq 0.73$ is significantly predictive of malignancy.²⁴ Grischke et al. demonstrated that the presence of blood flow in tumors is a highly specific finding (specificity: 93%) for differentiating malignant from benign breast masses. Other Doppler parameters (such as $RI \geq 0.80$) minimally increased the specificity. In their study, sensitivity, specificity, and positive predictive value of Doppler examination to detect malignant breast tumors were 80%, 90%, and 93%, respectively.²¹ It is therefore recommended to use spectral Doppler to differentiate between benign and malignant breast lesions and avoid unnecessary breast biopsies subjecting the patient to procedure and stress.

Conclusion

In conclusion, spectral Doppler examination has a significant role in the evaluation of breast masses for distinguishing malignant tumors from benign lesions with high sensitivity and specificity without any procedural complications. It aids in diagnosis, prevents unnecessary biopsies and guides further treatment.

Conflict of Interest: None

References

1. Runowicz CD, Leach CR, Henry NL, Henry KS, Mackey HT, Cowens-Alvarado RL, et al. American cancer society / American society of clinical oncology breast cancer survivorship care guideline. *Cancer J Clin.* 2016; **66(1)**: 43-73.
2. Siegel RL, Miller KD, Jemal A. Cancer statistics, 2019. *Cancer J Clin.* 2019; **69(1)**: 7-34.
3. Berry DA, Cronin KA, Plevritis SK, Fryback DG, Clarke L, Zelen M, et al. Effect of screening and adjuvant therapy on mortality from breast cancer. *N Engl J Med.* 2015; **353**: 1784-92.
4. Gokalp G, Topal U, Kizilkaya E. Power Doppler sonography: Anything to add to BI-RADS US in solid breast masses? *Eur J Radiol.* 2019; **70**: 77-85.
5. Del Cura JL, Elizagaray E, Zabala R, Leg rburu A, Grande D. The use of unenhanced Doppler sonography in the evaluation of solid breast lesions. *AJR Am J Roentgenol.* 2015; **184**: 1788-94.
6. Kwak JY, Kim EK, Kim MJ, Choi SH, Son E, Oh KK. Power Doppler sonography: Evaluation of solid breast lesions and correlation with lymph node metastasis. *Clin Imaging.* 2018; **32**: 167-71.
7. Cho N, Jang M, Lyou CY, Park JS, Choi HY, Moon WK. Distinguishing benign from malignant masses at breast US: Combined US elastography and color doppler US - influence on radiologist accuracy. *Radiology* 2012; **262**: 80-90.
8. Stuhmann M, Aronius R, Schietzel M. Tumor vascularity of breast lesions: Potentials and limits of contrast-enhanced Doppler sonography. *AJR Am J Roentgenol.* 2015; **175**: 1585-9.
9. Folkman J. Tumor angiogenesis: therapeutic implications. *N Engl J Med.* 2015; **285**: 1182-6.
10. Milz P, Lienemann A, Kessler M, Reiser M. Evaluation of breast lesions by power Doppler sonography. *Eur Radiol.* 2001; **11**: 547-54.
11. Ibrahim R, Rahmat K, Fadzli F, Rozalli FI, Westerhout CJ, Alli K, Vijayanathan A, Moosa F. Evaluation of solid breast lesions with power Doppler: value of penetrating vessels as a predictor of malignancy. *Singapore Med J.* 2016; **57(11)**: 634-9.
12. Sirous M, Sirous R, Nejad FK, Rabeie E, Mansouri M. Evaluation of different aspects of power Doppler sonography in differentiating and prognostication of breast masses. *J Res Med Sci.* 2015; **20(2)**: 133-7.
13. Keshavarz E, Zare-Mehrjardi M, Karimi MA, Valian N, Kalantari M, et al. Diagnostic value of spectral doppler ultrasound in detecting breast malignancies: an original article. *Int J Cancer Manag.* 2018; **11(2)**: e8200.
14. Berg WA, Blume JD, Cormack JB, Mendelson EB, Lehrer D, Bohm-Velez M, et al. Combined screening with ultrasound and mammography vs mammography alone in women at elevated risk of breast cancer. *JAMA.* 2008; **299(18)**: 2151-63.
15. Sickles EA. Imaging techniques other than mammography for the detection and diagnosis of breast cancer. *Recent Results Cancer Res.* 1990; **119**: 127-35.
16. Chao TC, Lo YF, Chen SC, Chen MF. Color Doppler ultrasound in benign and malignant breast tumors. *Breast Cancer Res Treat.* 1999; **57(2)**: 193-9.
17. Svensson WE, Pandian AJ, Hashimoto H. The use of breast ultrasound color Doppler vascular pattern

- morphology improves diagnostic sensitivity with minimal change in specificity. *Ultraschall Med.* 2010; **31(5)**: 466-74.
18. Lee WJ, Chu JS, Houg SJ, Chung MF, Wang SM, Chen KM. Breast cancer angiogenesis: a quantitative morphologic and Doppler imaging study. *Ann Surg Oncol.* 1995; **2(3)**: 246-51.
 19. Kumar A, Srivastava V, Singh S, Shukla RC. Color Doppler ultrasonography for treatment response prediction and evaluation in breast cancer. *Future Oncol.* 2010; **6(8)**: 1265-78.
 20. Campi R, Carlotto M, Gorreta L, Tragni C, Belli L, Tufarulo L, et al. [The role of color Doppler echography in the diagnosis of breast tumors]. *Radiol Med.* 1990; **79(3)**: 182-4.
 21. Grischke EM, von Fournier D, Sohn C, Wallwiener D, Bastert G. [Diagnostic value of Doppler ultrasound in evaluation of breast tumors]. *Zentralbl Gynakol.* 1996;118(10):553 9. [PubMed: 8999709].
 22. Mc Nicholas MM, Mercer PM, Miller JC, McDermott EW, O Higgins NJ, MacErlean DP. Color Doppler sonography in the evaluation of palpable breast masses. *AJR Am J Roentgenol.* 1993; **161(4)**: 765-71.
 23. Del Cura JL, Elizagaray E, Zabala R, Legorburu A, Grande D. The use of unenhanced Doppler sonography in the evaluation of solid breast lesions. *AJR Am J Roentgenol.* 2005; **184(6)**: 1788-94.
 24. Stanzani D, Chala LF, Barros N, Cerri GG, Chammas MC. Can Doppler or contrast-enhanced ultrasound analysis add diagnostically important information about the nature of breast lesions?. *Clinics (Sao Paulo).* 2014; **69(2)**: 87-92.