

# DIAGNOSTIC ACCURACY OF MULTISLICE COMPUTED TOMOGRAPHY IN BONY INVASION OF THE SQUAMOUS CELL CARCINOMA OF ORAL CAVITY

Sohaila Sarwat,<sup>1</sup> Junaid Iqbal,<sup>2</sup> Anam Naz,<sup>1</sup> Munazza Arain,<sup>1</sup> Anneqa Qureshi,<sup>1</sup> Muhammad Kashif Shazlee<sup>3</sup>

<sup>1</sup> Department of Radiology, Dr. Ziauddin University Hospital, Karachi, Pakistan.

<sup>2</sup> Department of Radiology, Aga Khan University Hospital (AKUH), Karachi, Pakistan.

<sup>3</sup> Department of Radiology, The Indus Hospital, Karachi, Pakistan.

PJR July - September 2022; 32(3): 142-147

## ABSTRACT

**INTRODUCTION:** Oral carcinoma is one of the greatest health problems globally with increasing prevalence. It is the second most common malignancy in both genders in Pakistan. They are responsible for approximately 200,000 deaths per year worldwide. The most common malignancy of the oral cavity is squamous cell carcinoma (SCC). In a recent study bony invasion by squamous cell carcinoma is found to be 53.3% in mandible, 15.5% in maxilla and 4.4% in both. One of the important roles of imaging is to detect bony invasion of oral SCC. The management of these patients depend upon the bony invasion. This aim of this study is to evaluate the diagnostic accuracy of the computed tomography in detecting the bony invasion of oral squamous cell carcinoma. Early detection is of utmost important in planning the treatment regimen to reduce the risk of distant metastasis and consequent morbidity and mortality. **MATERIAL AND METHODS:** This was a prospective cross sectional study conducted at the department of diagnostic radiology, Ziauddin medical university and hospital. 211 patients were included in our study who has oral squamous cell carcinoma referred to our radiology department for imaging. Multislice computed tomography was done, and assessment was made for bone invasion of the tumor. Histopathology was done as the gold standard. Sensitivity & specificity were calculated by comparing the results with histopathology. **RESULTS:** The sensitivity and specificity of the computed tomography for the detection of bone invasion were 97.11% and 89.7% respectively. **CONCLUSION:** Multislice computed tomography is a noninvasive imaging modality in early detection of bony invasion of oral squamous cell carcinoma with high accuracy. CT reconstruction with bone algorithm is accurate technique in detection of bony invasion.

**Keywords:** Multislice Computed Tomography, Oral carcinoma, Squamous cell carcinoma, Bony invasion.

## Introduction

Oral squamous cell carcinomas are the sixth most common cancers in the world.<sup>1</sup> The incidence rate of oral SCC has increased in recent times with highest incidence observed in Pakistan, France, India, and Brazil.<sup>2</sup> It is the second most common malignancy in both genders in Pakistan.<sup>3</sup> The incidence rate per

100,000 in Karachi is 21.3 in males and 19.3 in female.<sup>4</sup> They are responsible for approximately 200,000 deaths per year worldwide.<sup>5</sup> Squamous cell carcinoma is the most common histologic type of malignancy of oral cavity,<sup>6</sup> accounts for approximately 2.5 % of all malignancy and associated with alcohol and tobacco consumption.<sup>7</sup>

**Correspondence :** Dr. Junaid Iqbal  
Department of Radiology,  
Aga Khan University Hospital (AKUH),  
Karachi, Pakistan.  
Email: iqbal.junaid@aku.edu

Submitted 5 September 2022, Accepted 13 September 2022

Leukoplakia and sub mucosal fibrosis are considered as oral precancerous lesions with almost 2-12% chances of malignant transformation. Oral SCC is manifested in various clinical forms like leukoplakia, verrucous leukoplakia, erythroleukoplakia, necrotic ulcer with indurated edges or as an exophytic mass. Mostly they are painless unless secondarily infected.<sup>8</sup>

In Pakistan, oral cancers are among the commonest type of cancer. According to the reports published by Pakistan Medical Research Council (PMRC), oral SCC is the most common cancer among males and second common cancer in females after breast.<sup>9</sup> During the last few years it has been observed that this disease is appearing more in teenagers.<sup>10</sup> Major contributors for this increased incidence especially in younger individuals are various forms of chewable tobacco like pati, gutka and manpuri etc. The use of these chewing tobacco is high in almost all socio-economic classes.<sup>8</sup>

The role of imaging is not only to diagnose neoplastic lesion in oral cavity but also detect its bony invasion or infiltration, because bony invasion influences surgical planning. It is helpful for surgeon to decide for a marginal and segmental mandibulectomy, hemi mandibulectomy, partial maxillectomy and total maxillectomy.<sup>11</sup> Among various imaging modalities both computed tomography (CT) and magnetic resonance imaging (MRI) are commonly used to evaluate for bony invasion of oral SCC.<sup>12</sup> Modern CT technique with 1-2 mm sections is highly sensitive for the detection of bone invasion and aids in surgical treatment planning. If bone invasion is detected, a mandibulectomy seems always reasonable.<sup>13</sup> However, there is limited local data available regarding accuracy of computed tomography in detection of bony invasion of squamous cell carcinoma.

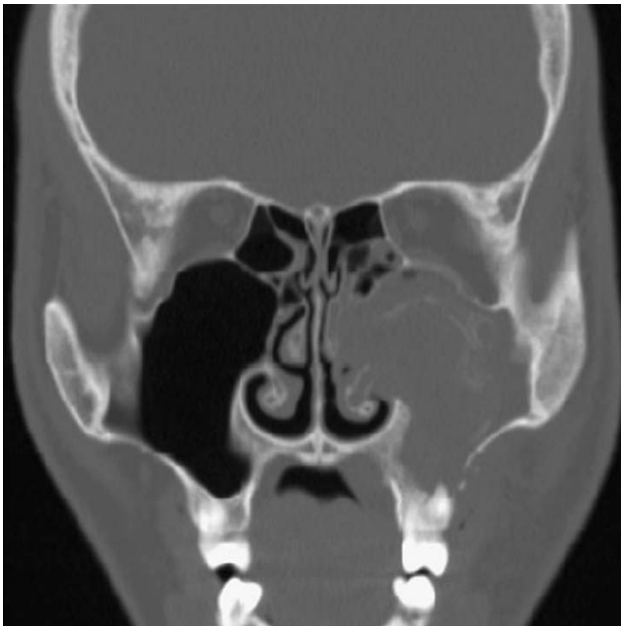
The increasing overall burden of oral cancers in Karachi and their fatal sequelae due to late detection of the progress of cancer warrant a better screening tool so this study helps in establishing the recent local data regarding sensitivity and specificity of multidetector computed tomography (MDCT) in early and accurate detection of bony invasion of oral squamous cell carcinoma as a non-invasive technique and comparing it with histopathology. Early detection is of utmost important in planning the treatment regimen to reduce the risk of distant metastasis and consequent morbidity and mortality.

## Material & Methods

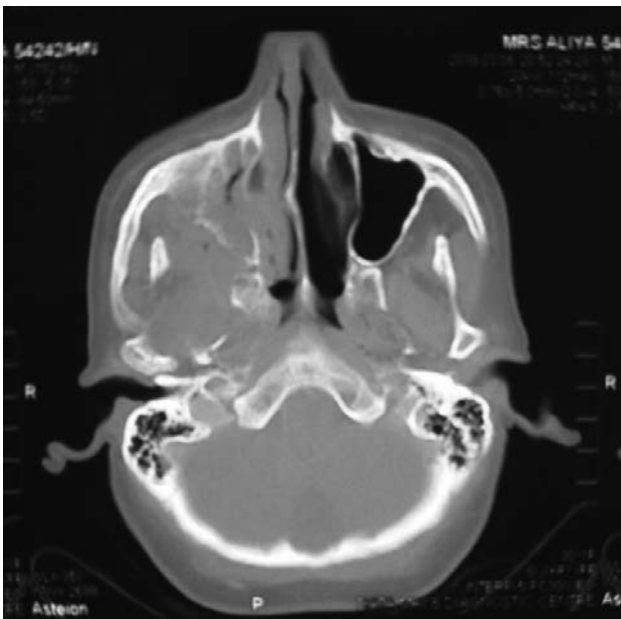
This was a prospective cross sectional study conducted at the department of diagnostic radiology, Ziauddin medical university and hospital from July 2017 to January 2018. 211 patients of either gender with biopsy proven squamous cell carcinoma of oral cavity were included in the study who referred to the department of radiology for CT scan. Post treatment patients (surgery or chemoradiation) were excluded from the study. Multislice computed tomography was done, and assessment was made for bone invasion of the tumor prior to surgery. All patients then had subsequent histopathology. All these patients were labeled as having bony invasion or otherwise based on multislice CT findings. The histopathological findings were then be compared with the findings of multislice CT scan to calculate sensitivity and specificity. The demographic data related to age and gender were also be recorded in proforma. Data was initially collected on proforma which was then entered into SPSS software. All analysis were done using SPSS version 22. Mean and standard deviations were calculated for continuous variables like age, duration of illness. Frequencies with percentages were calculated for categorical variables like sex, final diagnosis on biopsy and computed tomography. The binary variables of diagnosis of bony invasion on histopathology and computed tomography were cross tabulated to construct a 2x2 table. The 2x2 table was used to calculate sensitivity, specificity, positive predictive value, negative predictive value, and diagnostic accuracy. Effect modifiers like age, gender and duration of illness were controlled through stratification. Post stratification diagnostic accuracy were also calculated.

## Results

A total of 211 patients were included in the study. The ages ranged from 15 to 50 years and mean age was 39.23 – 1 years. The gender distribution showed that there were 145 (68.72%) males while 66 (31.27%) females. We found out that 112 patients showed evidence of bony invasion on multislice CT. 37 patients showed invasion in the maxilla 57 in the mandible

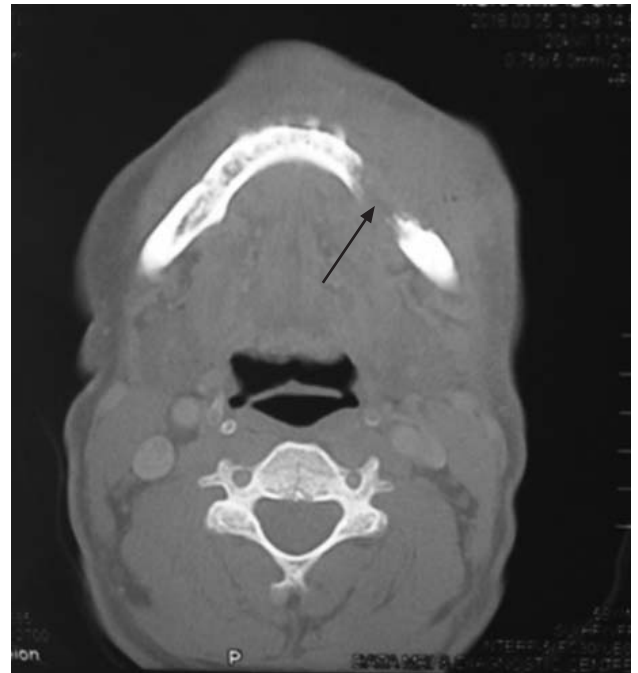


**Figure 1:** Coronal slice of CT scan showing the bony invasion of oral carcinoma in the maxilla and maxillary sinus.



**Figure 2:** Mass showing erosion and involvement of maxilla and maxillary sinus

while 18 in both. Histopathology confirmed that a total of 101 patients showed bony invasion of the squamous cell carcinoma. 33 of them showed invasion of the maxilla, 53 of the mandible while 15 patients showed invasion in both. Multislice CT correctly identified 33/37 invasions of the maxilla while 53/57 of the mandibular invasions and 15/18 in both. Thus, the sensitivity



**Figure 3:** Left sided oral carcinoma invading left mandible (arrow).

of the computed tomography was 97.11%. On the other hand, computed tomography truly identified 96/99 cases without bony invasion making the specificity as 89.7%. The overall diagnostic accuracy of the multislice computed tomography was 93.3%. Positive and negative predictive values for a diagnosis of SCC with bony invasion on computed tomography were 90.1% and 96.96% respectively. (Tab.1)

Sensitivity	Specificity	PPV	NPV	Diagnostic Accuracy
97.11%	89.7%	90.1%	96.96%	93.3%

**Table 1:**

## Discussion

Oral squamous cell carcinoma (OSCC) is a multi-factorial disease with increasing incidence globally. Some of the proven causative factors are tobacco, alcohol and human papilloma virus, the prognosis of disease is determined by various factors ranging from demographics to molecular markers. In many literatures authors have tried to prove the correlation of some factors or group of independent factors with prognosis of patients with oral carcinoma. But none of the factor can alone influence the prognosis of disease. For the prognosis of patient with oral cancer

all the factors should be considered including demographics, general physical factors, clinical factors, histological factors, and molecular factors.<sup>14</sup>

Oral cancer represents only 3% of all malignant tumours,<sup>15</sup> but it has very high mortality rate with a 5-year survival rate of less than 60%.<sup>16</sup> Squamous cell carcinoma (SCC) is the most common histopathological type, represents around 90% of malignant tumors of the oral cavity, predominantly in the mandible, with more than 300,000 new cases diagnosed each globally.<sup>17</sup>

Oral SCC shows rapid growth that is why radiological imaging is mandatory in addition to clinical examination.<sup>18</sup> The radiological imaging helps in the assessment of tumor size, thickness, depth, extension<sup>19</sup> as well as bony invasion or infiltration. A tumor is a three-dimensional structure and for surgical planning size and extension of tumor in all three dimensions are mandatory for surgeon in obtaining cancer-free margins.<sup>20</sup>

Various radiologic imaging techniques are available for the determination of oral cancer along with its extension, computed tomography (CT) and magnetic resonance imaging (MRI) are best imaging modalities available for the detection of head and neck tumors.<sup>18</sup> The choice largely depends on the local availability and expertise. One of the important role of imaging in patients with oral squamous cell carcinoma is to detect the presence of bony invasion, as it influences surgical planning. It is helpful for surgeon to plan for a marginal and segmental mandibulectomy, hemi mandibulectomy, partial maxillectomy and total maxillectomy.<sup>11</sup>

In 2013 S Uribe, et al in a study on accuracy of imaging modalities for detection of bony invasion in patients with oral squamous cell carcinoma and it showed the diagnostic accuracy of 85.7 - 86.7 % on CT scan, 87.0% on PET/CT and 85.7-87.0% on MRI.<sup>17</sup>

In 2006 Imaizumi et al had also shown excellent result in a comparative study for mandibular invasion in CT Vs MRI. He reported sensitivity of CT 100% and specificity 88%, PPV 89% and NPV 100%.<sup>11</sup> These accuracy measures are higher than any other study. It is chiefly because of Imaizumi et al had taken 5 mm and 1mm thickness in axial section of CT scan along with soft tissue and bone algorithm images he had also added Dental CT, CT software program spe-

cifically developed to evaluate multiple panoramic and cross-sectional images of the jaw bone. Sliker et al in their study yielded the sensitivity of CT scan in detecting bony invasion is 92% with specificity of 87%.<sup>21</sup> Mukherji et al. concluded the sensitivity of CT scan is 96%, specificity 87%, positive predictive value 89% and negative predictive value 95%.<sup>22</sup>

It should be considered that, although studies of diagnostic accuracy are necessary and are available as well, but they are not sufficient for making imaging policy or fixed protocols.<sup>23</sup> However, after evaluation of new diagnostic techniques they should incorporate in imaging protocols not only for enhancement of image quality but also help in making the decisions about treatment.<sup>24</sup>

There are some limitations of CT in diagnosing superficial lesion that only abutting against adjacent bone, hence full staging process should include clinical examination and imaging. And there is always a need for refinement in imaging techniques and modalities that can provide accurate information approaching gold standard, in this respect further studies can be done in this regard. Magnetic resonance imaging & Fused PET/CT may be useful.

## Conclusion

The key findings of our study suggested that multislice computed tomography is highly reliable in detecting the bony invasions in oral squamous cell carcinoma. Use of this rapid, nonoperator dependent & highly accurate examination may decrease delays in appropriate management and guides in defining the disease extent as well as helps in deciding which surgical approach to be used.

**Conflict of Interest:** None

## References

1. Warnakulasuriya S. Global epidemiology of oral and oropharyngeal cancer. *Oral Oncol* 2009; 45 (4-5): 309-16.
2. Dil N, Banerjee AG Knockdown of aberrantly expressed nuclear localized decorin attenuates

- tumor angiogenesis related mediators in oral cancer progression model in vitro *Head Neck Oncol.* 2012; **4**: 11.
3. Ahmed u, Khawer A, Ahmed J, Ajmal M, Bangash WK, Akhtar M. Occult metastasis in carcinoma of oral cavity, *J Coll Physician Surg Pak*, 2007; **17(6)**: 313-5.
  4. Bhurgri Y, Bhurgri A, Usman A, Pervez S, Kyani N, Bashir I. Epidemiological review of head and neck cancer in Karachi. *Asian Pacific J Cancer Prev* 2006; **7**: 195-200.
  5. Jamal S, Mamoon N, Mushtaq S, Luqman M. Oral cancer: clinocopathological analysis of 723 cases. *Pak Armed Forces Med J.* 2006; **56(3)**: 295-9.
  6. Khan M, Qaimud din, Salam A. Niswar as a risk factor in the aetiologly of oral cancer, *J Pak Dent Assoc.* 2007; **16(2)**: 77-81.
  7. Madana J, LalibertØ F, Morand GB, Yolmo D, Black MJ, MlynarekAM,etalComputerized tomography based tumor-thickness measurement is useful to predict postoperative pathological tumor thickness in oral tongue squamous cell carcinoma. *J Otolaryngol Head Neck Surg.* 2015; **44**: 49.
  8. Nair UJ, Nair J, Mathew B, Bartsch M. Glutathione S-transferase M1 and T1 null genotypes as risk factors for oral leukoplakia in ethnic Indian betel quid/tobacco chewers. *Carcinogenesis* 1999; **20(5)**: 743-48.5
  9. Alamgir M, Jamal Q, JafareyN.A, Mirza T.Clinicopathological Parameters Of 50 Oral Squamous Cell Carcinoma Cases in Karachi. *Pak J Med Dent* 2013; **2(02)**: 3-8.
  10. Bhurgri Y, Bhurgri A, Nishter S, Ahmed A, Usman A, Pervez P et al. Pakistan - Country profile of cancer and cancer control 1995-2004. *J Pak Med Assoc.* 2006; **56(3)**: 124-30.
  11. Imaizumi A, Yoshino N, Yamada I, Nagumo K, Amagasa T, Omura K, Okada N, Kurabayashi T. A potential pitfall of MR imaging for assessing mandibular invasion of squamous cell carcinoma in the oral cavity. *American journal of neuro-radiology.* Jan 2006; **27(1)**: 114-22.
  12. Patrick KH, Hadeib A, Goldenberg D, Jacene H, Patel P. The role of positron emission tomography and computed tomography fusion in the management of early - stage and avanced - stage primary head and neck squamous cell Carcinoma. *Arch Otolaryngol Head Neck Surg* 2006; **132**: 12-6.
  13. Handschel J, Naujoks C, Depprich RA, K bler NR, Kr pil P, Kuhlemann J, Jansen TM, Boeck I, Sproll KC. CT-scan is a valuable tool to detect mandibular involvement in oral cancer patients. *Oral oncology.* Apr 2012; **48(4)**: 361-6.
  14. Jadhav KB, Gupta N. Clinicopathological prognostic implicators of oral squamous cell carcinoma: need to understand and revise. *North American journal of medical sciences.* Dec 2013; **5(12)**: 671.
  15. de Camargo Cancela M, Voti L, Guerra-Yi M, Chapuis F, Mazuir M, Curado MP. Oral cavity cancer in developed and in developing countries: Population-based incidence. *Head & neck.* Mar 2010; **32(3)**: 357-67.
  16. Warnakulasuriya S. Living with oral cancer: epidemiology with particular reference to prevalence and life-style changes that influence survival. *Oral oncology.* Jun 2010; **46(6)**: 407-10.
  17. Uribe S, Rojas LA, Rosas CF. Accuracy of imaging methods for detection of bone tissue invasion in patients with oral squamous cell carcinoma. *Dentomaxillofacial Radiology.* 2013 Apr; 30; **42(6)**: 20120346.
  18. Genden EM, Ferlito A, Silver CE, Takes RP, SuÆrez C, Owen RP, Haigentz M, Stoeckli SJ, Shaha AR, Rapidis AD, Rodrigo JP. Contemporary management of cancer of the oral cavity. *European Archives of Oto-Rhino-Laryngology.* Jul 2010; **267(7)**: 1001-17.
  19. Vogel DW, Zbaeren P, Thoeny HC. Cancer of the

- 
- oral cavity and oropharynx. *Cancer Imaging*. 2010; **10(1)**: 62.
20. Park JO, Jung SL, Joo YH, Jung CK, Cho KJ, Kim MS. Diagnostic accuracy of magnetic resonance imaging (MRI) in the assessment of tumor invasion depth in oral/oropharyngeal cancer. *Oral oncology*. May 2011; **47(5)**: 381-6.
21. Slieker FJB, Dankbaar JW, Bree Rd, Cann EMV. Detecting Bone Invasion of the Maxilla by Oral Squamous Cell Carcinoma: Diagnostic Accuracy of Preoperative Computed Tomography Versus Magnetic Resonance Imaging. *Journal of Oral and Maxillofacial Surgery*. September 2020; **78(9)**: 1645-52.
22. Mukherji SK, Isaacs DL, Creager A, Shockley W, Weissler M, Armao D. CT detection of mandibular invasion by squamous cell carcinoma of the oral cavity. *AJR Am J Roentgenol* 2001; **177**: 237-43.
23. Kim IH, Patel MJ, Hirt SL, Kantor ML. Clinical research and diagnostic efficacy studies in the oral and maxillofacial radiology literature: 1996-2005. *Dentomaxillofacial Radiology*. Jul 2011; **40(5)**: 274-81.
24. Uribe S. The impact of imaging technologies on temporomandibular joint disorder diagnosis. *Evidence-based dentistry*. Dec 2011; **12(4)**: 113.