

UNILATERAL PULMONARY AGENESIS: A VERY RARE CONGENITAL ENTITY. CASE REPORT OF TWO CASES AND REVIEW OF LITERATURE

Umaima Majeed, AbdulSattar, Sadia Anjum, Zahida Zaffar, Musserat Javed

Department of Radiology, Nishtar Medical College & Hospital, Multan, Pakistan.

PJR July - September 2014; 24(3): 101-104

ABSTRACT

We report two cases of unilateral pulmonary agenesis. Both patients, 4 months old male child (case 1) and 18 months old female child (case 2), presented with shortness of breath with recurrent respiratory infections in later. Chest examination revealed impaired percussion note with absent breath sounds on affected side. CT chest with coronal reformation revealed unilateral absence of lung parenchyma with ipsilateral absent bronchus in case 1 and rudimentary in case 2. Survey of associated congenital abnormalities revealed horseshoe kidney in one patient (case1). We report these cases with special emphasis on MDCT with 3D reformation.

Key Words: Pulmonary agenesis, MDCT, Associated anomalies

Introduction

Lung agenesis is a rare congenital anomaly, is often associated with acute respiratory distress, and has a high mortality rate.¹ It represents failure of development of the primitive lung bud. With about 300 cases reported in the literature, this malformation has an estimated frequency between 1/10,000 to 1/15,000 autopsies, its occurrence is usually sporadic in most of cases, but parental consanguinity has been reported by Mardini and Nyhan.² Pulmonary agenesis may be isolated or be part of an association such as VACTERL sequence (vertebral anomalies, anal atresia, cardiac defects, tracheoesophageal fistula, renal anomalies, and limb anomalies).^{3,4}

appeared to be small and bell shaped, there was decreased movement of right hemithorax, ipsilateral tracheal shift, impaired percussion note and absent breath sounds on right side. He was investigated with CT thorax with 3D reconstruction. It showed agenesis of right lung and right bronchus with hyperinflation of left lung which was seen herniating to the contralateral side. Right hemithorax was seen occupied by heart. Based on these findings, diagnosis of lung agenesis was made (Fig. 1a, 1b, 1c). Upon survey for associated congenital anomalies, horseshoe kidney was found (Fig. 1d).

Case 1

A 4 months old male child presented with history of shortness of breath. On examination, right hemithorax

Correspondence : Dr Umaima Majeed
Department of Radiology
Nishtar Medical College & Hospital,
Multan, Pakistan.
Mob.: 0321-7350662
Email: dr.umaima1@gmail.com

Submitted 12 February 2015, Accepted 9 March 2015

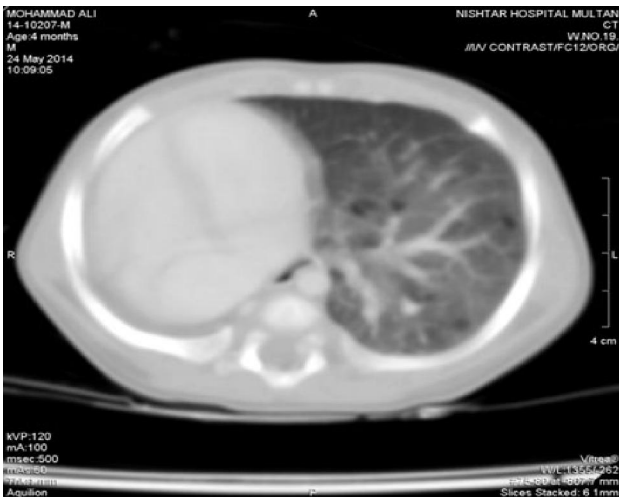

Figure 1a: CT chest, axial section; showing absence of lung parenchyma on right side with mediastinal shift to the right side. Left lung is hyperinflated and seen herniating to right side.

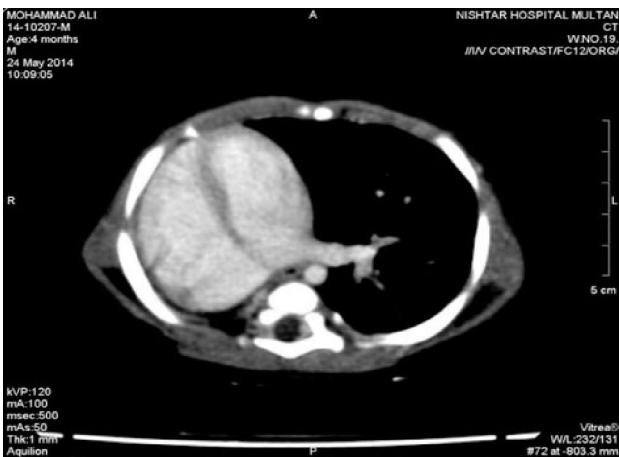

Figure 1b: CT Chest, mediastinal window showing agenesis of right lung. Left lung is hyperinflated and herniated to right side. Heart is seen occupying right hemithorax

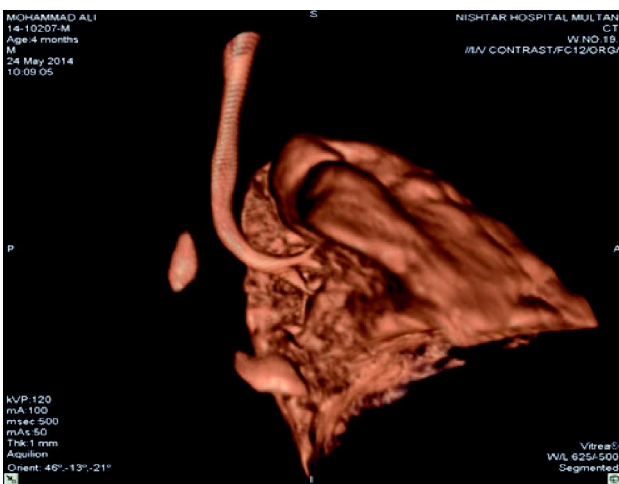


Figure 1c: CT Chest 3D Reconstruction: showing Agenesis of right lung and right bronchus. Trachea is continuing as left main bronchus.

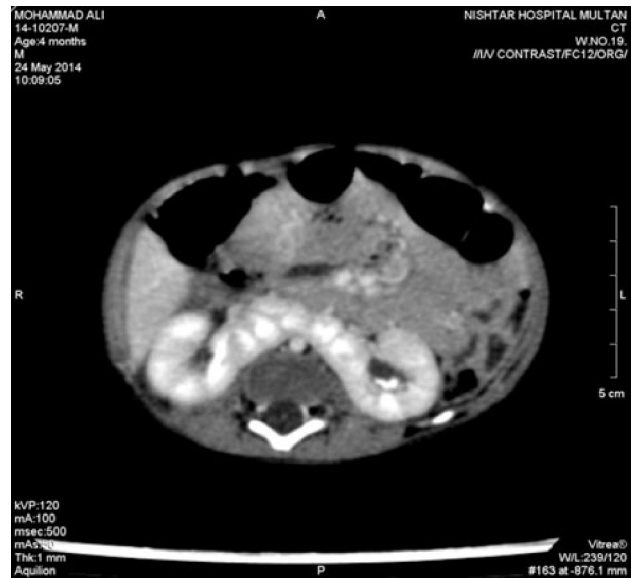

Figure 1d: CT abdomen of same patient showing Horseshoe kidney.

Case 2

An 18 months old female child presented with history of respiratory distress and recurrent chest infections. Her general physical examination revealed pallor and tachypnea. Chest examination showed impaired percussion note and absent breath sounds on left side. There were few coarse inspiratory crackles at right lung base. Routine blood examination showed neutrophilia, however sonography of abdomen and

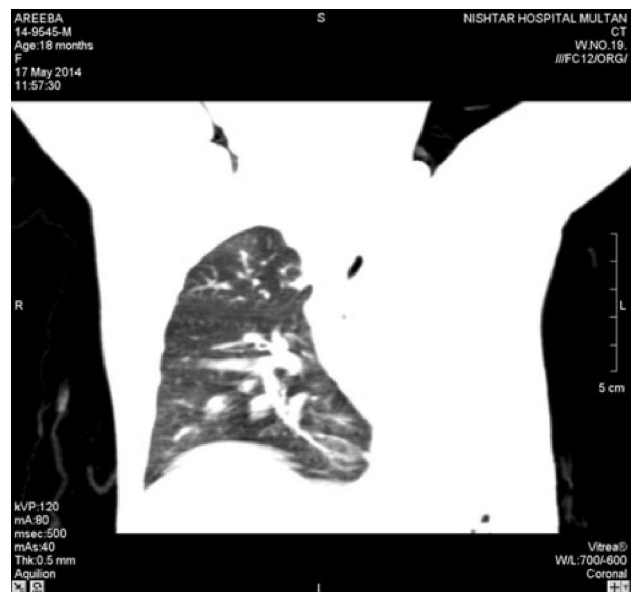


Figure 2a: CT Chest coronal reformat showing absence of lung parenchyma on left side.

echocardiography of heart were normal. CT chest performed with 3D reconstruction. It showed agenesis of left lung with hyperinflation of right lung which was seen herniating to the left side. There was mediastinal shift to the left side. Rudimentary left bronchus was seen. No other congenital abnormality was found. (Fig. 2a, 2b, 2c)

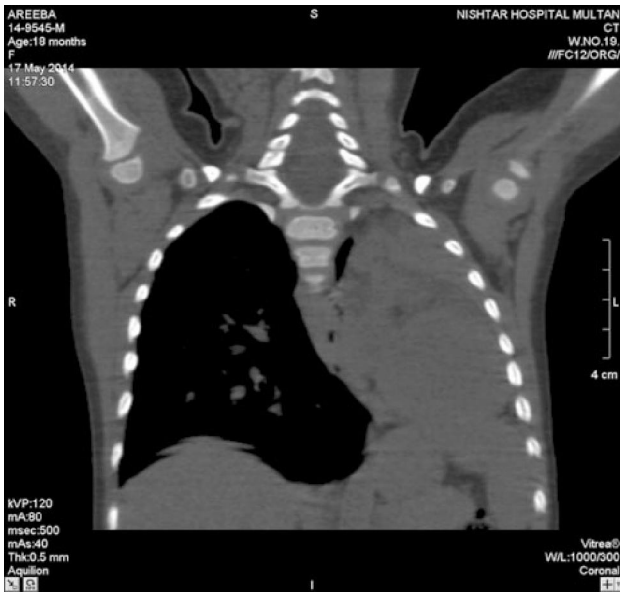

Figure 2b: CT chest coronal reformat showing absence of left lung with hyperinflation of right lung.

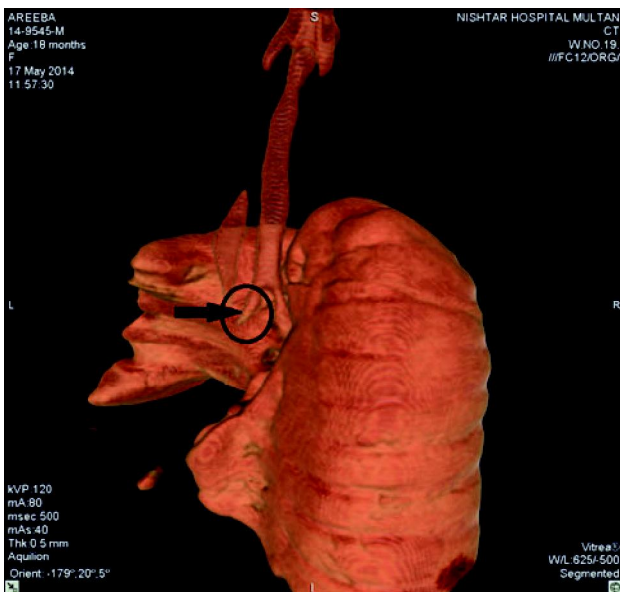


Figure 2c: CT chest 3D reconstruction showing agenesis of left lung with hyperinflated right lung herniating to left side. A rudimentary left bronchus is also seen (arrow)

Discussion

Pulmonary agenesis is a rare congenital malformation of lung development that was first described by De Pozzein 1673 from a necropsy of an adult female. It is defined as complete absence of lung tissues, bronchi, and pulmonary vessels.⁵ It may be unilateral or bilateral, partial, or complete. The exact cause of pulmonary agenesis remains unknown, it seems to result from multiple factors that may be genetic, viral, teratogenic insults (vitamin A deficiency), and mechanical,^{6,7} There is a 1.3 : 1 female predominance with unilateral agenesis. Left sided agenesis is more common and these subjects have a longer life expectancy than those with right sided agenesis.⁸ This is probably due to excessive mediastinal shift and malrotation of carina in right sided agenesis which hinders proper drainage of the functioning lung and increases chances of respiratory infections. In unilateral lung agenesis, the trachea continues directly into the main bronchus of the normally developed lung, and respiratory distress usually occurs due to retention of bronchial secretions and inflammations.¹ Associated malformations, mainly affecting the cardiovascular, gastrointestinal, and musculoskeletal systems, influence the prognosis of these patients, as well as the location of the missing lung.⁹

Schneider¹⁰ classified agenesis into three groups, which has been subsequently modified by Boyden.¹¹ Depending upon the stage of development of the primitive lung bud, pulmonary agenesis is classified into three categories:

- Type 1 (Agenesis) - Complete absence of lung and bronchus and no vascular supply to the affected side.
- Type 2 (Aplasia) - Rudimentary bronchus with complete absence of pulmonary parenchyma.
- Type 3 (Hypoplasia) - Presence of variable amounts of bronchial tree, pulmonary parenchyma and supporting vasculature.

Our patients would classify as Type 1 (Case 1) and Type 2 (Case 2) pulmonary agenesis.

Nearly 50% cases of pulmonary agenesis have associated congenital defects¹² involving cardiovascular, skeletal, gastrointestinal and genitourinary system. One of the two patients had associated horseshoe kidney. (Fig. 1d)

Conclusion

Unilateral pulmonary agenesis is a rare congenital entity sometimes associated with other congenital anomalies. MDCT with 3D reconstruction has a great role in its timely diagnosis and classification. Right-sided agenesis has worse prognosis probably due to excessive mediastinal shift and malrotation of carina which hinders proper drainage of the functioning lung and increases chances of respiratory infections. In addition, there is also higher incidence of co-existent cardiac and vascular anomalies. Overall survival of children with left-sided pulmonary agenesis is compatible with normal life provided close multi-disciplinary followup is organized.

References

1. Kumar B, Kandpal DK, Sharma C, Sinha DD. Right lung agenesis. African Journal of Paediatric Surgery. 2008; **5(2)**: 102-4.
2. Mardini MK, Nyhan WL. Agenesis of the lung. Report of four patients with unusual anomalies. Chest 1985; **87**: 522-7.
3. Maymon R, Schneider D, Hegesh J, et al. Antenatal sonographic findings of right pulmonary agenesis with ipsilateral microtia: A possible new laterality association. Prenat Diagn 2001; **21**: 125-8.
4. Milani D, Selicorni A. Right pulmonary agenesis with ipsilateral microtia: A new laterality association or part of the oculoauriculovertebral spectrum? Prenat Diagn 2002; **22**: 1053-4.
5. Schneider P, Schwabbe E. Die morphologie der missbildung des menschen und der thiere, Jena: G Fischer 1912; **3**: 812-22.
6. Maltz DL, Nadas AS. Agenesis of the lung: Presentation of eight new cases and review of the literature. Pediatrics 1968; **42**: 175-88.
7. Maden M. Retinoids in lung development and regeneration. Curr Top Dev Biol 2004; **61**: 153-89.
8. Oymada A, Gasul B.M, Holinger P.M. Agenesis of the Lung. Am J Dis Child. 1953; **85**: 182-7.
9. Ootaki Y, Yamaguchi M, Oshima Y, Yoshimura N, Oka S. Pulmonary agenesis with interrupted aortic arch. Annals of Thoracic Surgery. 2001; **72(5)**: 1742-44.
10. Schneider P, Schwabbe E. E. Die Morphologie der Missbildungen Des Menschen Under Thiere. Jena: Gustav Fischer. 1912; **3**: 817-22.
11. Boyden E. Developmental anomalies. AM. J. Surg, 1955; **89**: 79-88.
12. Sbokos C.B., McMillan IRK. Agenesis of the lung. Brit J Dis Chest. 1977; **3**: 183-97.