

# COMPLETE DUPLICATION OF URINARY BLADDER IN SAGGITAL PLANE ALONG WITH TYPE 3 URETHREL DUPLICATION: RARE CASE REPORT

Ameet Kumar Lalwani, Aroon Tharani, Syed Muhammad Faig

Department of Radiology, Sindh Institute of Urology and Transplantation (SIUT), Karachi, Pakistan.

PJR January - March 2022; 32(1): 32-35

## ABSTRACT

Urinary bladder duplication along with urethral duplication is a rare congenital abnormality. It is usually associated with various other congenital anomalies of anorectal and spinal cord. As our knowledge, at least 300 cases were reported in the literature. It is affecting predominately males and mostly diagnosed in childhood or adolescence. We are reporting rare case presentation of renal transplant patient, come to know just after transplant due to lack of association with other congenital anomalies.

**Keywords:** Duplication of urinary bladder and urethra.

## Introduction

The duplication of the lower urinary tract is rare congenital anomaly denoting to the duplication of the urinary bladder or the urethra.

Abrahamson was the first who presented classification bladder duplication.<sup>1</sup> He classified these congenital anomalies to either complete duplication of the bladder (two bladders and two separate urethras) and incomplete duplication with two bladders and a common urethra.

In order to separate true bladder duplication from other anomalies such as bladder diverticula or multilocular bladders, the septum between the two bladders must include muscular tissue.

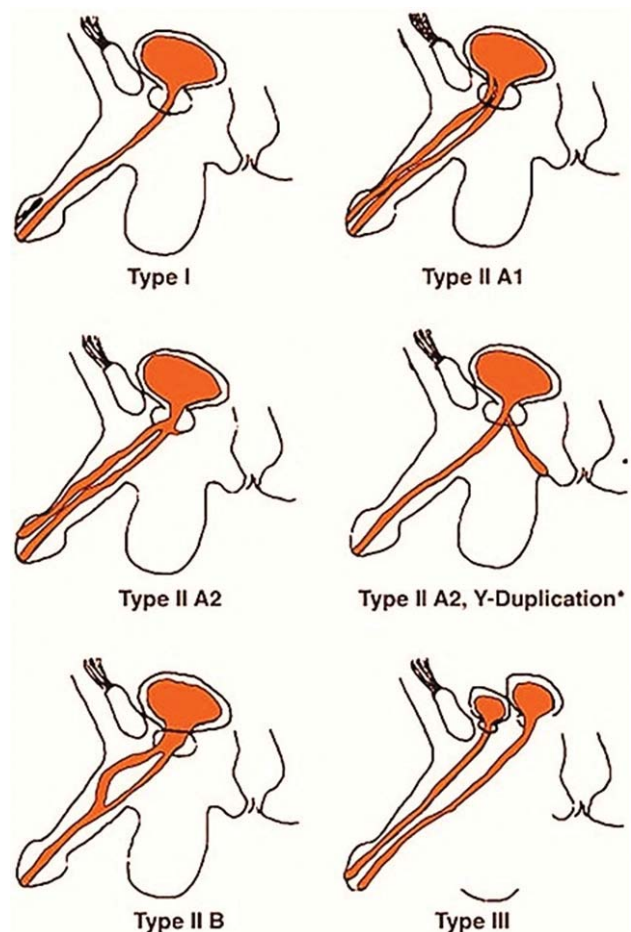
Urethral duplication may be complete or incomplete and the most widely accepted classification of the different types of urethral duplication was developed by Effman et al. (Fig. 1).<sup>2</sup>

## Case Presentation

17 years boy known case of end stage renal disease had past surgical history of right nephrectomy pre-

**Correspondence :** Dr. Ameet Kumar Lalwani  
Department of Radiology,  
Sindh Institute of Urology and Transplantation (SIUT),  
Karachi, Pakistan.  
Email: dramitsl@gmail.com

Submitted 19 November 2021, Accepted 5 January 2022



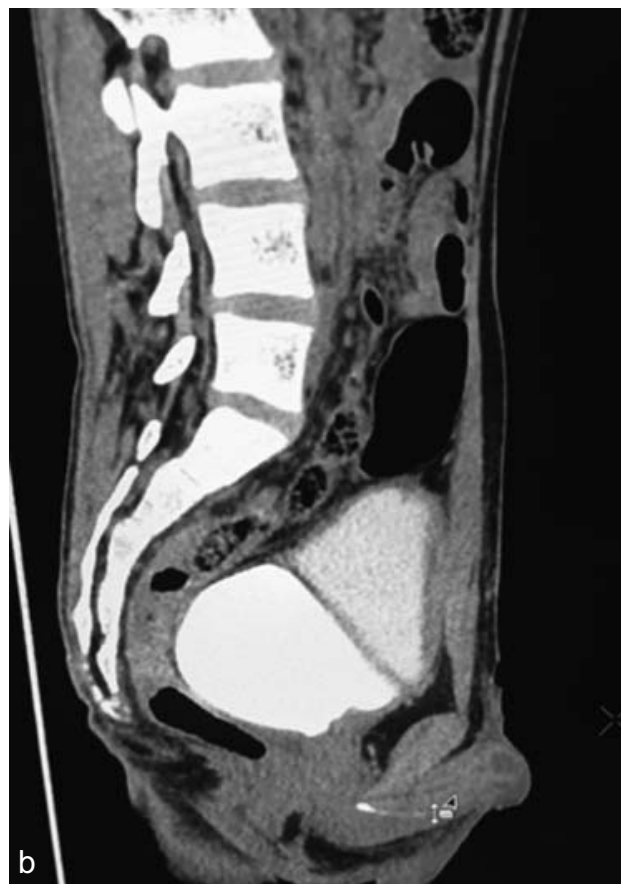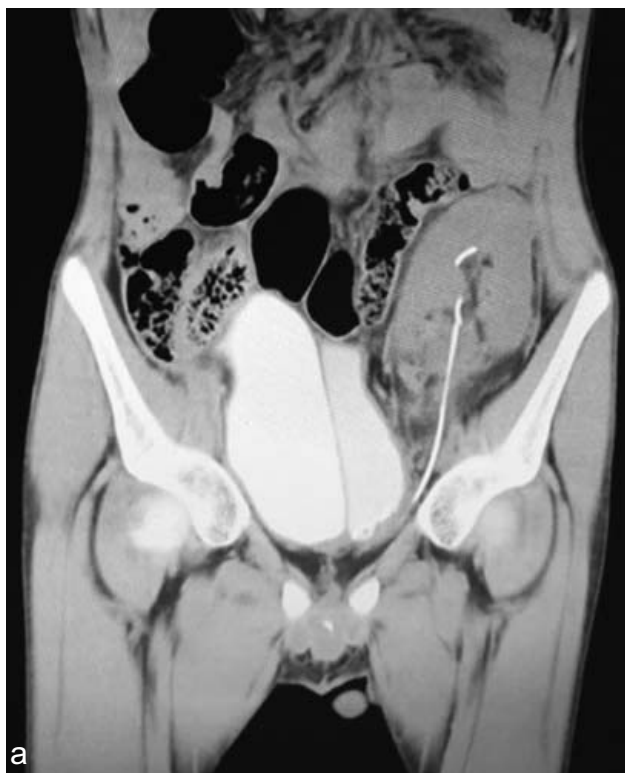Picture courtesy: [https://www.europeanurology.com/issue/S0302-2838\(07\)X0067-8](https://www.europeanurology.com/issue/S0302-2838(07)X0067-8)

sented in SIUT (Sindh institute of urology and transplantation) for renal transplant.

He had also history of hypospadias. For pre transplant workup cystoscopy was done which showed dilated hypospadias meatus and stricture at distal penile urethra. Stricture was dilated with guide wire. Membranous and prostatic urethra was normal and mild trabeculations seen in the urinary bladder.

Patient was received renal transplant after that and Double J (DJ) stenting was placed during time of renal transplant. After ten days of renal transplant cystoscopy was done for removal of DJ stent but surgeon faced difficulty so CTscan was advised.

**Radiological imaging:** CT Pyelogram with additional urogram phase was performed to locate DJ stent, which showed incidental duplication of urinary bladder with a septa traversing whole length of urinary bladder. Distal loop of DJ was seen in left hemi half of the urinary bladder, while proximal loop of DJ seen in pelvicalyceal system of graft kidney with mild residual fullness. So these findings in urinary bladder were suggestive of double urinary bladder (Fig.2).



**Figure 2:** Reformed coronal and sagittal CT scan Images showing urinary bladder duplication in sagittal plane with left Transplanted kidney ureter with DJ draining into left hemi half of urinary bladder.

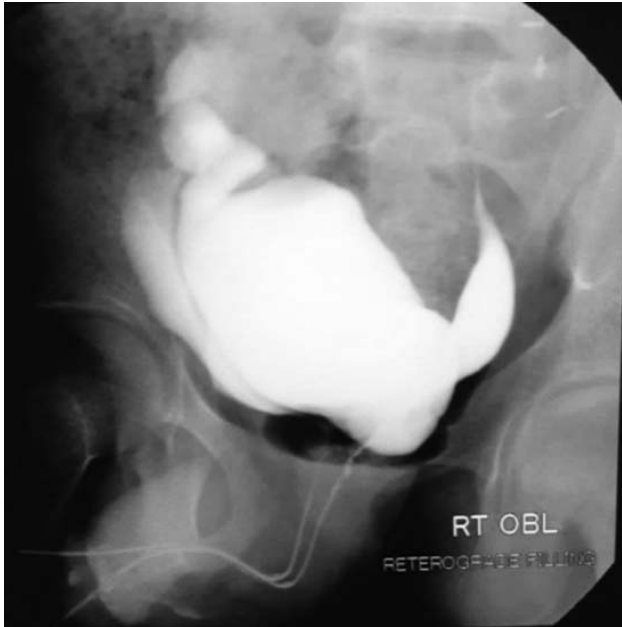So CT scan urogram was confirmed duplication of urinary bladder and each urinary bladder received the ureter of ipsilateral native kidneys.

For the further evaluation Urethrogram was advised to rule out partial or complete duplication of urethra. Urethrogram was performed under all aseptic measures. Feeding tube was placed at the external meatus which was identified on the ventral surface of the mid penile region as already known case of hypospadias. Contrast was injected which outlined the urinary bladder on right side of the hemi pelvis. Upon further instillation of contrast, anterior urethra was noted to bifurcating into two tracts.

Another feeding tube was used to access this bifurcation upon further instillation of contrast which outlined another urinary bladder cavity in left hemi-

pelvis. The two urethra were draining both bladders separately (Fig.3).

So, all these findings are suggestive of Type III urethra complete duplication with saggital type urinary bladder duplication.



**Figure 3: Retrograde Urethrogram:** The two urethra were draining both bladders separately. Both urinary bladder lied side by side and reflux of contrast also noted in left ureter.

## Discussion

Urinary bladder duplication along with urethral duplication is rare congenital anomaly. Bladder duplication is classified in two types as saggital or coronal planes. Bladder duplication in the saggital plane is more common with the two bladders side by side, each receiving urine from one ureter.<sup>3</sup> Duplication in the coronal plane is less often.

The cause of complete duplication of the urinary bladder remains obscure, although a few hypotheses have been proposed. Abrahamson offers 2 explanations:

Excessive constriction between the urogenital and vesicourethral portions of the ventral cloaca.

A supernumerary cloacal septum that indents the epithelial of the urinary bladder.

Disturbances in the embryogenesis of the hindgut may result in duplication of the lower urinary tract.<sup>4</sup>

Being a congenital, mostly the diagnosis was established in childhood or adolescence but nearly never in adult age.<sup>5</sup> In our case unique as it is not associated with any major anomaly, only associated with hypospadias so that diagnosed late. The urethral duplication has multiple presentations, with a lack of specificity going from the asymptomatic, deformed penis, twin streams, urinary tract infection, and symptoms of bladder outlet obstruction to various other signs like a renal failure as one of the worst.<sup>6</sup>

Associated abnormalities with complete duplication of the urinary bladder include duplication of the penis, vagina, uterus, lumbar vertebrae and hindgut. In addition, there may be fistulous connection between the rectum, vagina and urethra.

Surgical correction is treatment of choice if major complaints or symptoms. Overall prognosis is good, only need follow up.

## Conclusion

Duplication of urinary bladder along with complete duplication o urethra is rare congenital anomaly; it usually presents in childhood usually associated other anomalies like anorectal, penis and spinal cord. Reconstructive surgery should be done to improve quality of life in associated anomalies.

**Conflict of Interest:** None

## References

1. J. Abrahamson, Double bladder and related anomalies: clinical and embryological aspects and a case report, *British Journal of Urology*, 1961; **(33)**: pp. 195-214.
2. Effmann EL, Lebowitz RL, Colodny AH. Duplication of the urethra. *Radiology*. 1976; **119(1)**: 179-85.
3. A. M. Coker, M. J. Allshouse, and M. A. Koyle, Complete duplication of bladder and urethra in a saggital plane in a male infant: case report and

---

literature review, *Journal of Pediatric Urology*, 2008; (4): pp. 255-9.

4. Okur H, Keskin E, Zorludemir U, Olcay I. Tubular duplication of the hindgut with genitourinary anomalies. *J Pediatric Surg*. 1992; **27**: 1239-40.
5. Dayanc M, IrkilataHC, Kibar Y, BozkurtY, BasalS, XhafaA. Y-type urethral duplication presented with perineal fistula in a boy. *GMS Ger Medical Sci* 2014; **16**: 149-51.
6. Macedo Jr 1 A, Rondon A, Bacelar H et al. Urethral duplication II-A Y type with rectal urethra: ASTRA approach and tunica vaginalis flap for first stage repair. *Int Braz J Urol*. 2012; **38**: 707.