

DETERMINE DIAGNOSTIC ACCURACY OF MULTISLICE CT SCAN IN DETECTION OF BONY INVASION OF SQUAMOUS CELL CARCINOMA OF ORAL CAVITY

Muhammad Imran Siddiqui, Muhammad Misbah Tahir, Amanullah Khan, Muhammad Ayub Mansoor

Department of Diagnostic Imaging, Liaquat National Hospital (LNH), Karachi, Pakistan.

PJR January - March 2015; 25(1): 01-06

ABSTRACT

OBJECTIVE: To determine the diagnostic accuracy of multislice computed tomography in detecting bony invasion of squamous cell carcinoma of the oral cavity. **METHODS:** We enrolled 80 biopsy proven patients of oral squamous cell carcinoma who underwent multislice computed tomography at department of diagnostic radiology, Liaquat National Postgraduate Medical Centre from July 2011 till December 2011. Lesions were assessed for bony involvement of maxilla & mandible. A total of 69 patients underwent surgery after computed tomography. Sensitivity, specificity, positive and negative predictive values were calculated by comparing the computed tomography results with histopathology. Around 11 patients who did not have surgery were excluded from the study. **RESULTS:** Multislice CT correctly identified invasion of the maxilla in 9 out of 9 patients (9/9), invasion of mandible in 30 out of 32 patients (30/32), invasion of maxilla and mandible in 4 out of 4 patients. Thus the sensitivity of the computed tomography was 95.55%. On the other hand, computed tomography correctly detected 24 out of 25 cases without bony invasion making the specificity as 95.85%. **CONCLUSION:** Multislice computed tomography is an accurate modality for detecting bony invasion of squamous cell carcinoma of the oral cavity. **Key words:** Bony invasion, CT, squamous cell carcinoma, oral cavity

Introduction

Prevalence and mortality rates of oral carcinoma are rising worldwide. The annual incidence is more than 3,000,000 new cases, globally.¹ For lip and oral cavity cancer only, the incidence rates are lowest in Eastern Asia and highest in South-Central Asia. Its prevalence is estimated to be 40% of all cancers in South East Asia.¹ It is the second commonest cancer in both males and females in Pakistan.¹ Oral carcinoma is responsible for approximately 200'000 deaths per year world wide.² Squamous cell carcinoma is the most common malignant tumor of the oral cavity^{1,3} In a study by Musani et al bony invasion by cheek

carcinoma is found to be 53.3% in mandible, 15.5% in maxilla and 4.4% in both.¹

The important role of imaging for patients with squamous cell carcinoma of oral cavity is the evaluation of presence and extension of bony invasion as it influences surgical planning and prognosis. Different surgical excisions like marginal and segmental mandibulectomy, hemimandibulectomy, partial maxillectomy and total maxillectomy can be planned depending upon extension of bone involvement.^{1,4} Among various imaging modalities both computed tomography (CT) and magnetic resonance imaging (MRI) are commonly used to evaluate bony invasion of squamous cell carcinoma of oral cavity.^{4,5} There

Correspondence : Dr. Muhammad Imran Siddiqui
Department of Diagnostic Imaging,
Liaquat National Hospital (LNH),
Karachi, Pakistan.
Ph: 0300-8943895
Email: drimrandow@gmail.com

Submitted 30 March 2015, Accepted 18 April 2015

is no Pakistani data available regarding accuracy of computed tomography in detection of bony invasion of squamous cell carcinoma of oral cavity. Best of our knowledge this is the first study evaluating accuracy of CT in detecting involvement of both maxilla and mandible by oral squamous cell carcinoma. Previous studies have evaluated involvement of mandible only.

Computed tomography can identify the location and extent of tumor along with presence or absence of distant metastasis. Ability of multislice computed tomography to scan the head & neck in single breath hold combined with a better resolution and elimination of breathing and miss registration artifacts has made it modality of choice for evaluating bone invasion by oral carcinoma. Properly performed and accurately interpreted imaging study can significantly influence clinical management besides becoming cost effective.

Methods and Material

We enrolled 80 biopsy proven patients of oral squamous cell carcinoma who underwent multislice computed tomography at department of diagnostic radiology, Liaquat National Postgraduate Medical Centre from July 2011 till December 2011 in this study. Sixty-nine of these patients underwent surgery after CT. Eleven patients who did not have surgery were excluded from the study. CT was performed on Toshiba Asteion 16 multislice CT scanner. Images were acquired before and after intravenous contrast administration. Informed consent was taken from all patients. Approval from ethical committee of our institution was also obtained. Scanning was performed in axial and coronal planes by a CT technician having at least five year experience in body imaging. Non-ionic iodinated contrast (Iopamiro 370, Bracco s.p.a. Italy) was given at a dose of 1.5 - 2.0 ml per kg with power injector at rate of 2.0 - 3.0 ml per second. Patient's allergy status and creatinine level were taken into account before giving contrast. Scanning protocol was 3 mm section thickness, collimation 3 mm, reconstruction interval 3mm, scan delay 80 seconds, 450 mA and 100 to 150 Kv. Scanned field was from base of skull to thoracic inlet. Images were reviewed by a radiologist who had more

than five year experience of cross sectional body imaging. Images were reviewed on diagnostic monitor in soft tissue and bone algorithm and in axial, sagittal and coronal planes. The criterion for bony invasion was erosion, lysis or destruction of the cortex of the adjacent bone. Per-operatively, representative sections of the tumor-bone interface and the bony margins were submitted. Pathologist with more than five year experience in oncology reviewed the specimens.

Data was initially collected on performa which was then entered into SPSS software. All analysis were done using SPSS version 15. Mean and Standard deviations were calculated for continuous variables like age. Frequencies with percentages were calculated for categorical variables like sex, final diagnosis on biopsy and computed tomography. The binary variables of diagnosis of bony invasion on histopathology and computed tomography were cross tabulated to construct a 2 x 2 table. The 2 x 2 table was used to calculate, sensitivity, specificity, positive predictive value, negative predictive value and accuracy.

Results

A total of 69 patients were included in this study. Age ranged from 32 to 73 years (mean age 53.84 years, SD \pm 10.208). There were 38 (55.0%) males and 31 (45.0%) females. Distribution of squamous cell carcinoma of oral cavity was as follows: 45(65.21%) lesions in buccal mucosa; 7 (10.14%) in alveolar ridge; 7(10.14%) in tongue; 5 (7.24%) in floor of mouth; 5 (7.24%) in hard palate. Forty-four out of 69 patients showed evidence of bony invasion on multislice CT. Nine and 31 patients exhibited invasion of maxilla and mandible respectively, while 4 had involvement of both. Bony invasion of the squamous cell carcinoma was found in 45 patients on histopathology. Multislice CT correctly identified 9/9 invasions of the maxilla, 30/32 of the mandibular invasions and 4 out of 4 lesions involving both maxilla and mandible. Thus the sensitivity of the computed tomography was 95.55%. On the other hand, computed tomography truly identified 23/24 cases without bony invasion making the specificity as 95.85%. The Overall diagnostic accuracy of the multislice Computed

Tomography was 95.65%. Positive and negative predicative values for a diagnosis of SCC with bony invasion on CT were 97.7% and 92.0% respectively. Correlation of CT findings with histopathology is given in the (Tab. 1).

	Histopathology +ve	Histopathology -ve	
CT+ve	43	01	Total CT+ve (44)
CT-ve	02	23	Total CT-ve (25)
	Total Histopathology +ve 45	Total Histopathology -ve 24	Total Patient 69

True Positive, n = 43
 False Positive, n = 01
 True Negative, n = 23
 False Negative, n = 02

Table 1: Correlation of histopathology & computed tomography

Discussion

The development of modern imaging techniques has significantly altered the treatment and management of malignancies of oral cavity and other sites in head and neck region. Decisions which were once made intraoperatively are now made in advance by using information from cross sectional imaging techniques.⁶ The goal of imaging is to correctly determine the stage of tumor. Involvement of mandible or maxilla significantly affects the prognosis, morbidity and treatment planning. It is vital to detect the bone involvement before planning surgery as it changes the surgical approach. The imaging modality for evaluation of oral cancers has been a subject of debate and opinions and results vary with various authors.^{7,8} Some believe that use of MRI is superior to CT in evaluation of tumors especially when lesions are small, while many authors believe that CT and MRI are equally valuable in determining the extent of tumor.^{7,8,9} MRI may not be performed in patients with metallic implants and pacemakers. Swallowing, breathing artifacts and claustrophobia may hamper the examination. CT has the advantage of reduced examination time interval which also decreases the chances of motion artifacts. Tooth implants may produce artifacts obscuring the imaging details. Keeping the scanning plane parallel to the mandibular plane helps to eliminate artifacts caused by metallic dental restorations.¹⁰ The choice largely depends on the

local availability and expertise.

In early 1980s Larson et al¹¹ and Muraki et al^{12,13} described the radiological and sectional anatomy of the oral cavity. Lenz et al¹⁴ and Sigal et al¹⁵ discussed the role and usefulness of CT scanning in pathologies of oral cavity particularly carcinomas.

CT protocol for head and neck imaging with multislice spiral scanners has been described in detail by Baum et al.¹⁶ Thin-sections acquired with spiral multislice scanners after administration of IV contrast have shown to significantly improve the ability to evaluate oral cancers. Our protocol matches with the protocol described by Baum et al.¹⁶

Preoperative assessment of mandibular involvement provides crucial information to head and neck surgeons. Accurate information on status of mandible is necessary for proper patient counseling.^{17,18} Mandibular involvement has been widely studied and various imaging modalities have been used to determine whether patients are candidates for mandibular sparing procedures. Technical advances have made CT scan the examination most commonly used to detect mandibular involvement. Results have been variable regarding diagnostic accuracy of preoperative CT in this context. In 1986 Close et al¹⁹ reported a sensitivity of 100% specificity of 97% positive predictive value of 92% and negative predictive value of 100%.

In subsequent studies Shaha et al²⁰ reported diagnostic accuracy of 68% and Brown et al²¹ claimed a false negative rate of 28% arguing that the predictability and reliability of CT was disappointing. Later Lane et al²² reported sensitivity of 50% with negative predictive value of 61% suggesting that CT scan was inaccurate method for evaluating status of mandible.

In 2001 the study of Mukherji et al²³ showed promising results in this regard, they reported sensitivity of 96% specificity of 87% positive predictive value of 89% and negative predictive value of 95%.

In 2006 Imaizumi et al⁷ had also shown excellent result in a comparative study for mandibular invasion in CT Vs MRI. He reported sensitivity of CT 100% and specificity 88%, PPV 89% as well as NPV 100%. These accuracy measures are higher than any other study. It is chiefly because of Imaizumi et al had taken 5 mm and 1 mm thickness in axial section along with soft tissue and bone algorithm images.

He had also added dental CT, or dental scan, CT software program specifically developed to evaluate multiple panoramic and cross sectional images of the jaw bone.

This variability in results of different studies is most probably due to inconsistent imaging technique that was not optimal. Review of multiple previous studies using various imaging modalities for detecting bone invasion by squamous cell oral carcinoma has been given in (Tab. 2).

Study	Publication year	No. of patients	Slice thickness	Imaging modality	Sensitivity (%)	Specificity (%)	Accuracy (%)
Brown et al ²¹	1994	35	4-5mm	CT	53.3	100	72
Lane et al ²²	2000	26	5mm	CT	50	91.7	69.2
Mukherji et al ²³	2001	49	3mm	CT	96.2	87	91.8
Imaizumi et al ⁴	2006	51	5-1mm	CT	100	88	94
		51	3-4mm	MRI	96	54	74

Table 2: Review of studies using CT, MRI or both for detecting bone invasion by squamous cell oral carcinoma.

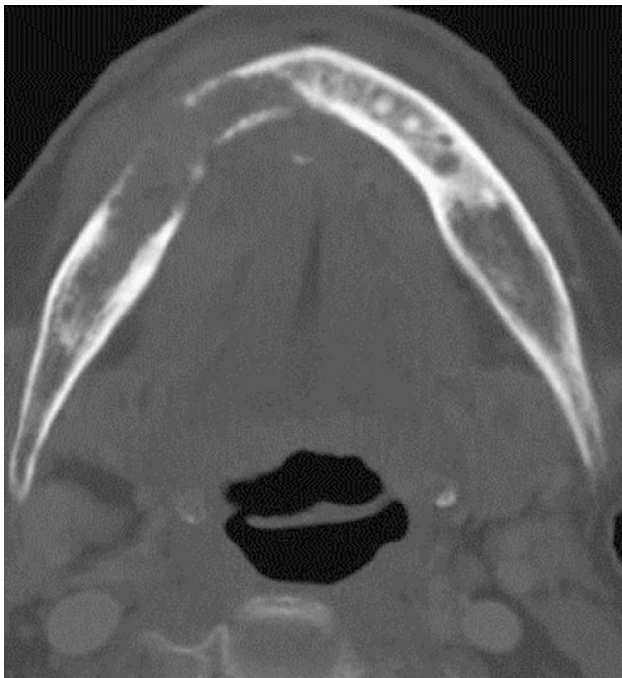

Figure 1: Axial section of CT scan (bone window) revealing oral carcinoma eroding adjacent mandible on right side.

The results of this study for evaluation of bony involvement (sensitivity 95.55%, specificity 95.85%, positive predictive value 97.7%, and negative predictive value 92%) are superior to studies of Brown et al,²¹ Shaha et al²⁰ and Lane et al.²² This in our belief is because of better imaging technique.

Brown et al²¹ and Lane et al²² acquired images by using 5 mm thick sections and did not routinely evaluate mandible with bone algorithms. Shaha et al²⁰ did not describe their CT technique. Close et al also obtained 5 mm thick contiguous sections, however if there was suspicion of bony involvement 3 mm sections were again obtained. Mukherji et al²³ acquired contiguous 3 mm images of all patients. Both Close et al¹⁹ and Mukherji et al²³ evaluated images on soft tissue and bone window settings.

The relatively higher sensitivities of CT noted in studies of Mukherji et al²³ and Imaizumi et al⁷ is most likely due to the fact that Mukherji et al²³ included only those patients who had carcinomas fixed to mandible on clinical examination and Imaizumi et al⁷ used an additional soft ware, Dental CT, or Denta scan that was not used in our study. There are some limitations of CT in diagnosing superficial lesion only abutting adjacent bone, hence full staging process should include clinical examination and imaging. And there is always a need for refinement in imaging techniques and modalities that can provide accurate information approaching gold standard. Further studies can be done in this regard. In selected cases use of another imaging modality like MRI in small lesions or Fused PET/CT may be useful.

On the other hand besides mandibular invasion we have also assessed the invasion of maxilla which was not done in previous studies. Although the cases of maxillary invasion are less than mandibular invasion but accuracy of CT for detecting maxillary invasion in our study is found to be higher than mandibular invasion. This is probably due to anatomic site of involvement of oral carcinoma and late presentation of patient for treatment.

Conclusion


Computed tomography is an imaging modality with high diagnostic accuracy, sensitivity and specificity in detecting bony invasion in oral squamous cell carcinoma. Use of this rapid, non operator dependent & highly accurate examination decreases delays in appropriate management and also guides in defining the disease extent and surgical approach.

The results of our study showed that CT is reliable technique for predicting bony invasion and may be

a helpful adjunct when considering mandibular or maxillary sparing procedures for carcinoma of the oral cavity. We believe that high diagnostic accuracy of CT can be consistently obtained only with high quality studies consisting of thin-section imaging, reconstruction and reformation of images in multiple planes, using both soft tissue and bone algorithm.

References

1. Musani MA, Jawad I, Marfani S, Khambaty Y, Jalisi M, Khan SA, Carcinoma Cheek: Regional Pattern and management, J Ayub Med Coll 2009; **21(3)**: 87-91.
2. Jamal S, Mamoon N, Mushtaq S, Luqman M. Oral cancer: Clinocopathological analysis of 723 cases. Pak Armed Forces Med J. 2006; **56(3)**: 295-9.
3. Khan M, Qaim ud din, Salam A. Niswar as a risk factor in the aetiology of oral cancer, J Pak Dent Assoc. 2007; **16(2)**: 77-81.
4. Imaizumi A, Yoshino N, Yamada I, Nagumo K, Amagas T, Omura K, et al. A potential pitfall of MR imaging for Assessing Mandibular invasion of Squamous cell carcinoma in the oral cavity. AJNR Am J Neuroradiol 2006; **2**: 114-22.
5. Patrick KH, Hadeib A, Goldenberg D, Jacene H, Patel P. The role of positron emission tomography and Computed Tomography Fusion in the management of Early - Stage and Avanced - Stage primary head and neck squamous cell Carcinoma. Arch Otolaryngol Head Neck Surg 2006; **132**: 12-6.
6. Mukherji SK, Castelijns J, Castillo M. Squamous cell carcinoma of the oropharynx and oral cavity: how imaging makes a difference. Semin Ultrasound CT MR 1998; **19(6)**: 463-75.
7. Sigal R, Zagdanski AM, Schwaab G, Bosq J, Auperin A, Laplanche A, et al. CT and MR imaging of squamous cell carcinoma of the tongue and floor of the mouth. Radiographics. 1996; **16**: 787-810.
8. Lenz M, Greess H, Baum U, Dobritz M, Kersting-Sommerhoff B. Oropharynx, oral cavity, floor of the mouth: CT and MRI. Eur J Radiol. 2000; **33**: 203-15.
9. Som PM. The present controversy over the imaging method of choice forevaluating the soft tissues of the neck. AJNR 1997; **18**: 1869-72.
10. Curtin HD, Ishwaran H, Mancuso AA, Dalley RW, Caudry DJ, McNeil BJ. Comparison of CT and MR imaging in staging of neck metastases. Radiology. 1998; **207**: 123-30.
11. Larsson SG, Mancuso A, Hanafee W Computed tomography of the tongueand floor of the mouth. Radiology 1982; **143**: 493-500.
12. Mancuso AA, Harnsberger HR, Muraki AS, Stevens MH. Computed tomography of cervical and retropharyngeal lymph nodes: normal anatomy, variants of normal, and applications in staging head and neck cancer. Part II: pathology. Radiology 1983; **148**: 715-23.
13. Muraki AS, Mancuso AA, Harnsberger HR, Johnson LP, Meads GB. CT of the oropharynx, tongue base, and floor of the mouth: normal anatomy and range of variations, and applications in staging carcinoma Radiology 1983; **148**: 725-31.
14. Lenz M, Hermans R. Imaging of the oropharynx and oral cavity. Part II: Pathology. Eur Radiol.1996; **6**: 536-49.
15. Sigal R, Zagdanski AM, Schwaab G, Bosq J, Auperin A, Laplanche A, et al. CT and MR imaging of squamous cell carcinoma of the tongue and floor of the mouth. Radiographics. 1996; **16**: 787-810.
16. Baum U, Greess H, Lell M, et al. Imaging of head and neck tumors – methods: CT, spiral-CT, multislice spiral-CT. Eur J Radiol 2000; **33**: 153-60.

-
- 
17. Mukherji SK, Pillsbury H, Castillo M. Imaging squamous cell carcinomas of the upper aerodigestive tract: what the clinicians need to know. *Radiology* 1997; **205**: 629-46.
 18. Zeman RK, Brink JA. Helical/Spiral CT. Technical Principles. In: Helical/Spiral CT, a practical approach. New York: McGraw Hill; 1995: 1-26.
 19. Close LG, Merkel M, Burns DK, Schaefer SD. Computed tomography in the assessment of mandibular invasion by intraoral carcinoma. *Ann Otol Rhinol Laryngol.* 1986; **95**: 383-8.
 20. Shaha AR. Preoperative evaluation of the mandible in patients with carcinoma of the floor of the mouth. *Head & Neck* 1991; **13**: 398-402.
 21. Brown JS, Grew NR. Predicting mandibular invasion in mouth cancer. *Clin Otolaryngol* **21**: 265-8. *Clin Otolaryngol Allied Sci* 1997; **22**: 558.
 22. Lane AP, Buckmire RA, Mukherji SK, Pillsbury HC, Meredith SD. Use of computed tomography in the assessment of mandibular invasion in carcinoma of the retromolar trigone. *Otolaryngol Head Neck Surg* 2000; **122**: 673 -7.
 23. Mukherji SK, Isaacs DL, Creager A, Shockley W, Weissler M, Armao D. CT detection of mandibular invasion by squamous cell carcinoma of the oral cavity. *AJR Am J Roentgenol.* 2001; **177**: 237-43.