

UNUSUAL PRESENTATION OF WILSON'S DISEASE. MRI BASED CASE REPORT AND REVIEW OF LITERATURE

Mahum Zaidi,¹ Rizwan Ajmal,¹ Bushra Rehan,¹ Muhammad Wasif²

¹ Department of Radiology, Liaquat National Hospital (LNH), Karachi, Pakistan.

² Department of Radiology, Aga Khan University Hospital (AKUH), Karachi, Pakistan.

PJR July - September 2019; 29(3): 211-214

ABSTRACT

This is a case of a 28 year old male, known case of Wilson's disease with CLD. He received D- Penicillamine for last 7 years but stopped treatment 6 months back. MRI done 7 years back showed features of high signals within caudate and lentiform nuclei. Fresh MRI brain was ordered which to our surprise showed atrophy of caudate and lentiform with regression in high signals as compared to previous scan along with this, subtle high signals on diffusion weighted images were seen in Parieto-occipital cortex bilaterally, which are not the usual sites of involvement in Wilson's disease.

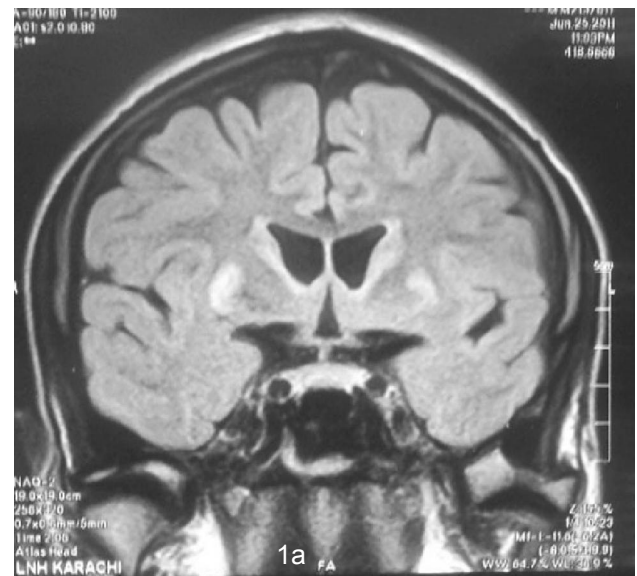
Introduction

Wilson disease is an autosomal recessive metabolic disorder. It is characterized by deficient biliary excretion of copper resulting in abnormal deposition in various tissues such as brain, liver, and cornea.¹ In brain Copper accumulates most frequently in the extra-pyramidal system, leading to disorders of movement.² The most common MR imaging abnormality in Wilson disease is the occurrence of high T1 signal intensity in the globus pallidus, putamen, and mesencephalon and high T2 signal intensity in the striatum.³ Here we present a case report with atypical presentation of Wilson's disease after 7 years of chelating therapy.

Case Summary

28 year old male patient known case of Wilson's disease and CLD, presented in ER with altered level of consciousness, lethargy and abdominal distension for 2 weeks. He was on D- Penicillamine therapy for last 7 years. He stopped treatment without medical advice 6 months back. His old lab workup showed reduced ceruloplasmin levels [0.07g/dl (n: 0.2-0.6)].

MRI done 7 years back showed typical features of high signals within caudate and lentiform nuclei DWI was normal. Kayser-Fleischer ring was present on slit-lamp ophthalmological examination.



Correspondence : Dr. Muhammad Wasif

Department of Radiology,
Aga Khan University Hospital (AKUH),
Karachi, Pakistan.

Email: mohammad.wasif@aku.edu

Submitted 1 August 2019, Accepted 21 August 2019

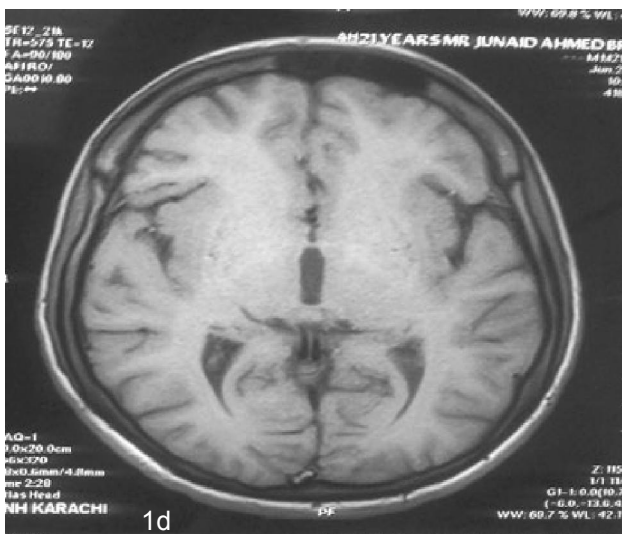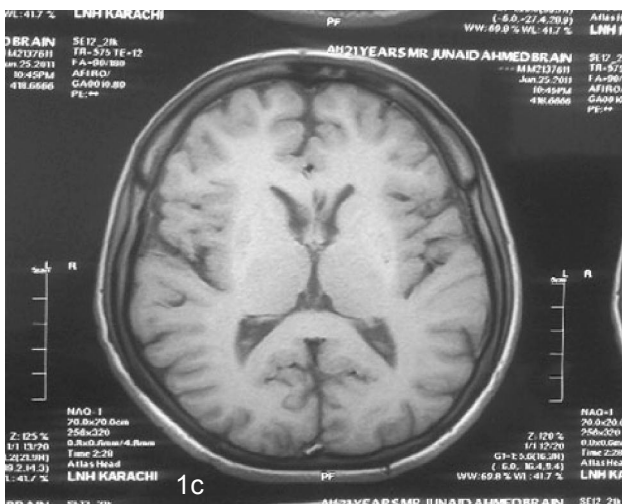
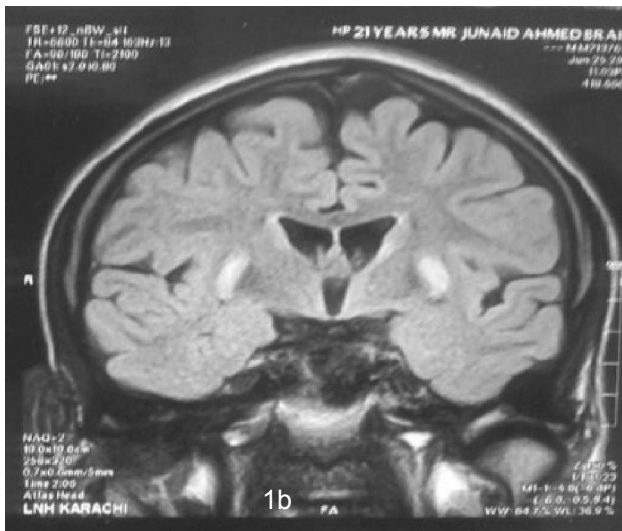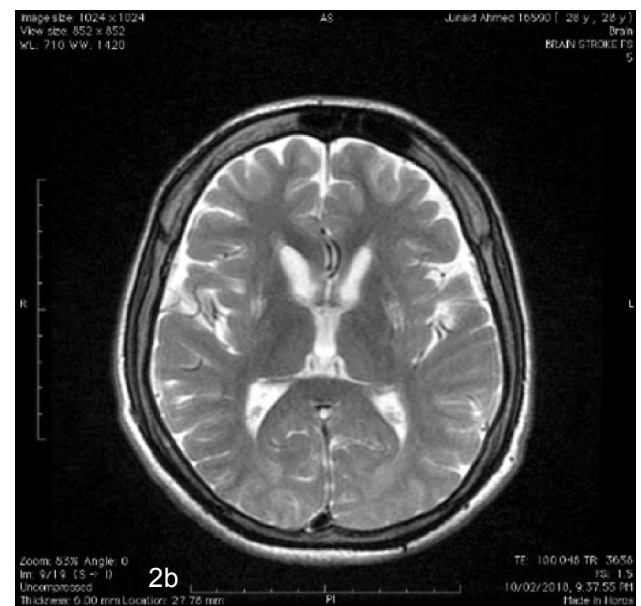
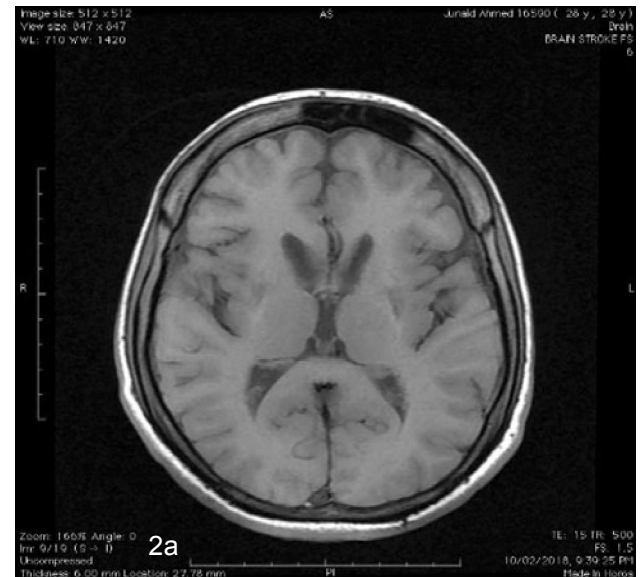


Figure 1a-1d: MRI brain 7 years back: FLAIR images showing bilateral symmetrical high signal intensity in caudate and lentiform

This time, on examination: He was disoriented, not obeying commands, had increased muscle tone, decreased powers in all 4 limbs, brisk reflexes and up going plantars. MRI brain was ordered which showed atrophy of caudate and lentiform with regression in high signals as compared to previous scan along with this, subtle high signals on diffusion weighted images were seen in Parieto-occipital cortex bilaterally. Recent lab findings again reveal normal serum copper levels and reduced ceruloplasmin levels [0.05g/l (Normal: 0.2-0.6)]. Kayser-Fleischer ring was still present on slit-lamp ophthalmological examination.



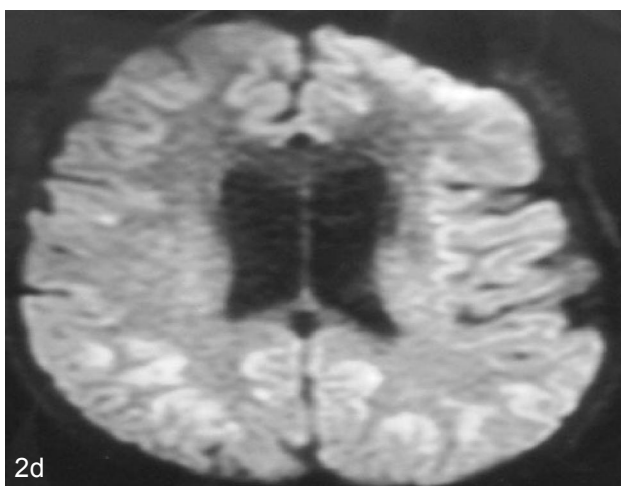
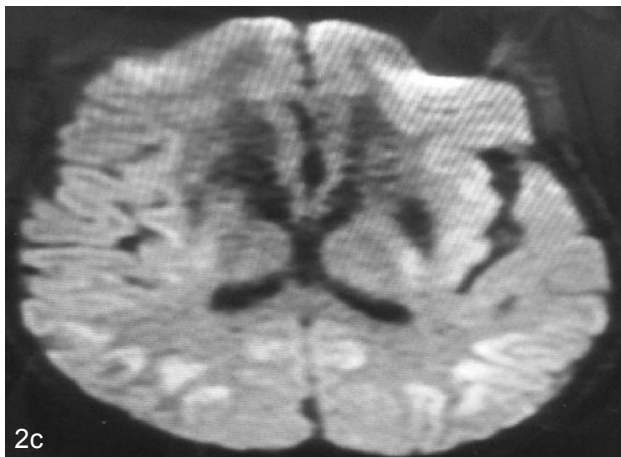


Figure 2a-2d: MRI brain after 7 years show atrophy of caudate and lentiform nucleus and subtle high signal intensity in bilateral parieto occipital cortices.

Discussion

Previous studies have reported that Wilson's disease most commonly presents with bilateral symmetric high signal intensity in the putamen, caudate nucleus, globus pallidus, claustrum, thalamus, cortical/sub-cortical regions, mesencephalon, pons, vermis, and dentate nucleus on T2-weighted images.⁴ Various studies have been submitted regarding typical and atypical appearance of Wilson's disease and literature has been published regarding reversibility of the lesions after early chelating therapy.⁵ Kozic DB et al in his study has summed up previous literature regarding atypical findings of Wilson's disease in which he has mentioned the contribution of many authors among which some showed high SI on T2W images

of the basal ganglia, brainstem, cerebellar peduncles, and supratentorial white matter.⁶ Van Wassenaer-van Hall et al and Braffman in their study presented cases of low signal intensity on T2W images of the globus pallidus, substantia nigra, red nucleus and corpus striatum.⁷⁻⁸ Van Wassenaer-van Hall et al and Saatci et al presented cases showing high SI on T1W images of the globus pallidus in patients with portosystemic shunt.⁷ Kozic et al in 2003 presented lesions with putaminal PDW signal elevation with neither T1W nor long echo T2W abnormalities.⁹ Kozic et al in 2014 evaluated the reversibility of MRI changes after early commencement of chelating therapy and he found out that the response was particularly impressive in brainstem structures, while the putaminal lesions were more resistant to D-penicillamine, especially in patients with later introduction of the treatment.⁵ In our case the patient was on long term D Penicillamine treatment which he stopped 6 months back. His current MRI showed that the lesions in caudate and putamen demonstrated partial regression with atrophy and subtle high signals on T1W images. However there was unusual appearance of symmetrical high signals in bilateral parieto occipital cortex on DWI AND FLAIR images.

Conclusion

With this case report we come to the conclusion that in patients with Wilson's Disease, brain MRI lesions may be completely or partially reversible during the long term D- Penicillamine therapy as is seen in previous data given by Kozic et al with likelihood of such resolution to be relatively higher if treatment started earlier in the course of the disease.

However if treatment is discontinued at any point of time new lesions can be seen to arise at unusual places as in our case they developed in bilateral Parieto occipital cortices with partial regression of lesions in caudate and putamen.

Conflict of interest: There are no financial arrangements or affiliation that would constitute a conflict of interest.

References

1. Starosta-Rubinstein S, Young AB, Kluin K, Hill G, Aisen AM, Gabrielsen T, Brewer GJ. Clinical assessment of 31 patients with Wilson's disease. *Arch Neurol*. 1987; **44**: 365-70.
2. Walshe JM, Yealland M. Wilson's disease: the problem of delayed diagnosis. *Journal of Neurology, Neurosurgery & Psychiatry*. Aug 1992; **55(8)**: 692-6.
3. Kim TJ, Kim IO, Kim WS, Cheon JE, Moon SG, Kwon JW, Seo JK, Yeon KM. MR imaging of the brain in Wilson disease of childhood: findings before and after treatment with clinical correlation. *American journal of neuroradiology*. Jun 2006; **27(6)**: 1373-8.
4. Sener RN. Diffusion MR imaging changes associated with Wilson disease. *American journal of neuroradiology*. May 2003; **24(5)**: 965-7.
5. Kozic DB, Petrovic I, Svetel M, Pekmezovic T, Ragaji A, Kostic VS. Reversible lesions in the brain parenchyma in Wilson's disease confirmed by magnetic resonance imaging: earlier administration of chelating therapy can reduce the damage to the brain. *Neural regeneration research*. Nov 2014; **9(21)**: 1912.
6. Kozic DB, Semnic R, Petrovic I, Svetel M, Ostojic J, Kostic VS. Are irreversible morphological signs of portal hypertension in neurological form of Wilson's disease associated with treatment delay? A pilot study. *Acta neurologica belgica*. Sep 2012; **112(3)**: 261-4.
7. Van Wassenae-van Hall HN, Van den Heuvel AG, Algra A, Hoogenraad TU, Mali WP. Wilson disease: findings at MR imaging and CT of the brain with clinical correlation. *Radiology*. Feb 1996; **198(2)**: 531-6.
8. Braffman BH. The aging brain and neurodegenerative disorders. In *Neuroimaging 2000* (pp. 951-978). Springer, New York, NY.
9. Kozic D, Svetel M, Petrovic B, Dragašević N, Semnic R, Kostic VS. MR imaging of the brain in patients with hepatic form of Wilson's disease. *European journal of neurology*. Sep 2003; **10(5)**: 587-92.