

# DIAGNOSTIC ACCURACY OF MAGNETIC RESONANCE SPECTROSCOPY (MRS) IN MALIGNANT BREAST LESIONS

Hassan Bukhari,<sup>1</sup> Nosheen Ahmad,<sup>1</sup> Irfan Shabbir,<sup>2</sup> Ibrahim Nasir Idrees<sup>3</sup>

<sup>1</sup> Department of Radiology, Allied Hospital, Faisalabad, Pakistan.

<sup>2</sup> Department of Radiology, DHQ Hospital, Faisalabad, Pakistan.

<sup>3</sup> Department of Radiology, Pakistan Institute of Medical Sciences, Islamabad, Pakistan.

PJR July - September 2019; 29(3): 194-201

## ABSTRACT

**OBJECTIVES:** A Descriptive cross-sectional study was conducted in the Department of Radiology Allied Hospital, Faisalabad from August 2014 to June 2015 to detect the diagnostic accuracy of magnetic resonance spectroscopy (MRS) in malignant breast lesions using histopathology as gold standard. **MATERIALS & METHODS:** A total of 110 patients with breast lesions on ultrasound (US) and on mammography and age 20-60 years were included. Patients who took chemotherapy for primary or secondary breast cancer, pregnant or breast feeding females, patients with renal failure and contraindication to MRS were excluded. All the patients were then underwent MRS on 1.5 tesla whole body MR imager. Breast lesion was considered as malignant if there was choline peak on magnetic resonance spectroscopy and choline/creatine ratio was >1.5. Magnetic resonance spectroscopy findings were correlated with histopathological findings. **RESULTS:** Mean age was  $49.31 \pm 6.76$  years. MRS supported the diagnosis of malignant breast lesions in 72 (65.45%) patients. Histopathology confirmed malignancy in 75 (68.18%) cases. In 72 MRS positive patients, 68 were True Positive and 04 were False Positive. Among, 38 MRS negative patients, 07 were False Negative whereas 31 were True Negative. Overall sensitivity, specificity, positive predictive value, negative predictive value and diagnostic accuracy of MRS in malignant breast lesions was 90.67%, 88.57%, 94.44%, 81.58% and 90.0% respectively. **CONCLUSION:** This study concluded that magnetic resonance spectroscopy is a highly sensitive and accurate modality for diagnosing malignant breast lesions, and has improved patient care by accurate and timely diagnosis for taking proper treatment options.

**Keywords:** Breast lesions, Imaging modality, Non-invasive, Magnetic Resonance Spectroscopy (MRS)

## Introduction

Patient complaints of breast lumps or lumpiness are common, ranging from 40% to 70% in women seeking advice. A breast lump, either self-detected, screen detected or clinician detected, raises the fear of breast cancer in any woman, irrespective of age.<sup>1</sup> Fortunately, the vast majority of breast lumps are benign, but this does not negate the need for evaluation of any palpable breast lesion.<sup>2</sup> The main motive behind the evaluation of such a newly detected palpable lump is basically to rule out malignancy. Evaluation of

breast lumps involves the rational use of a detailed history, clinical breast examination, imaging modalities and tissue diagnosis.<sup>1,2</sup>

Breast cancer is a type of cancer originating from breast tissue, most commonly from the inner lining of milk ducts or the lobules that supply the ducts with milk.<sup>3</sup> Breast cancer is most prevalent and is the leading cause of cancer related deaths among women worldwide. Its prevalence is 23% of all cancers in women.<sup>4</sup> The factors that contribute to the international

**Correspondence :** Dr. Ibrahim Nasir Idrees

Department of Radiology,  
Pakistan Institute of Medical Sciences,  
Islamabad, Pakistan.

Email: [ibrahimnasiridrees@gmail.com](mailto:ibrahimnasiridrees@gmail.com)

Submitted 7 July 2019, Accepted 29 August 2019

variation in incidence rates largely stem from differences in reproductive and hormonal factors and the availability of early detection services.<sup>5,6</sup> Breast cancer is more than 100 times more common in women than in men, although men tend to have poorer outcomes due to delays in diagnosis. The early and accurate diagnosis of breast cancer is crucial for successful treatment and to improve the quality of life.<sup>6</sup>

Noninvasive diagnosis of breast cancer remains a major clinical problem. In the case of a potential malignancy, imaging studies are useful to define the extent of the malignancy and to identify non-palpable masses elsewhere in the breast or on the contralateral side. These findings may alter the therapeutic approach, especially the choice of local therapy.<sup>7</sup> A variety of imaging modalities are currently available for the clinical use in breast lesions. Traditional approaches for the assessment of breast lesions have limited sensitivity and specificity. Since mammography, ultrasonography (US), and contrast-enhanced magnetic resonance imaging (MRI) are unable to reliably distinguish between malignant and benign tissues, the final diagnosis of cancer is most often based on histopathological analysis.<sup>8</sup> High-resolution anatomic magnetic resonance imaging (MRI) and dynamic contrast-enhanced MRI have evolved into a standard clinical tool for detection and diagnosis of breast lesions.<sup>9</sup>

Magnetic resonance imaging (MRI) is preferred when further characterization of these lesions is needed. In vivo proton MR spectroscopy (1H-MRS) is a non-invasive technique that has great potential to provide tumor metabolism, which may be used in tumor diagnosis and evaluating the therapeutic response of the tumor.<sup>10</sup> Magnetic resonance spectroscopy (MRS) allows biochemical characterization of scanned tissue and has been proved to be a sensitive method in identifying malignant tumours.<sup>11</sup> The diagnostic value of proton MR spectroscopy is typically based on determining the concentration of certain nuclei in metabolites and is most frequently based on the resonance frequency of hydrogen protons. Because the concentration of tissue, water, and lipids is several times the concentration of other metabolites, the signal from water and lipids is suppressed to uncover signal from low concentration compounds.<sup>12</sup> The sensitivity and specificity of MR Spectroscopy for

diagnosing malignant breast lesions is 90% and 89% (with Confidence Interval of 95%) 10 respectively while another study showed that sensitivity and specificity are 66% and 92% respectively.<sup>11</sup>

Since there was controversy and no local study available on this, so this study would help us to determine the diagnostic accuracy of magnetic resonance spectroscopy (MRS) in diagnosing malignant breast lesions in local population. Moreover, this study would also add non-invasive techniques in early diagnosis and timely treatment of malignant breast lesions in order to reduce morbidity and pure diagnostic biopsies in breast lesions which would consequently reduce complications of such procedures.

## Materials and Methods

After approval from ethical review committee, total number of 110 patients who were referred by clinician to the Radiology department of Allied Hospital, Faisalabad, fulfilling the inclusion/exclusion criteria were selected. Female patients with 20-60 years of age with breast lesions on US (presence of all of the following; spiculations, deeper than taller, punctuate calcifications, duct extension and non-compressibility) and on mammography (all of the following; irregular shape, low fat density, indistinct margins and speculations) were recruited in the study. Non-probability, consecutive sampling technique was used for patient selection. Patients who took chemotherapy for primary or secondary breast cancer and patients having general contraindication to MRS (i.e. MRS incompatible prosthesis or cardiac pacemaker holders) and patients with renal failure were excluded from the study.

After taking informed written consent and relevant history, proton magnetic resonance spectroscopy (1H MRS) was performed in every patient using 1.5 Tesla whole body MR system with gradient strength of 33 mT/m and IV contrast (gadovist) was injected at the rate of 0.1 ml/Kg body weight for acquisition of scan. A fast scout scan in sagittal, axial, and coronal planes were obtained. The scan technique used was the point-resolved spectroscopy single-voxel technique. It was followed by water suppression pulses to be followed by data acquisition. Each MRS was interpreted and the breast lesion was considered as malignant if there was choline peak on magnetic

resonance spectroscopy and choline/creatine ratio was >1.5. Magnetic resonance spectroscopy findings were correlated with histopathology report. Any of the following findings on histopathology was considered as positive for malignancy; cellular atypia (pleomorphism), mitotic activity, increase in nuclear cytoplasmic ratio. 75 patients were diagnosed of malignant lesions on histopathology report; out of them, 48 were diagnosed of invasive ductal carcinoma, 15 were having ductal carcinoma in situ, 9 were of invasive lobular carcinoma, 3 were having mucinous adenocarcinoma.

Collected data was analyzed through computer software SPSS 19.0. Mean and standard deviation was calculated for quantitative variables i.e. age. Frequency and percentage was calculated for qualitative variables i.e. true positive and true negative. 2x2 contingency table was used to calculate sensitivity, specificity, positive predictive value and negative predictive value and diagnostic accuracy in diagnosing malignant breast lesions taking histopathology as gold standard. Effect modifiers like age was controlled through stratification and post-stratification chi square was applied. P value ≤ 0.05 was considered as significant.

Diagnostic accuracy and parameters were assessed by the following table and formulas;

Histopathology	MRS	
	Positive	Negative
Positive	True positive	False Negative
Negative	False positive	True Negative

**Table 1:** Diagnostic accuracy and parameters assessment

$$\text{Sensitivity} = \frac{\text{TP}}{\text{All positive cases on histopathology}} \times 100$$

$$\text{Specificity} = \frac{\text{TN}}{\text{All negative cases on histopathology}} \times 100$$

$$\text{Positive Predictive Value (PPV)} = \frac{\text{TP}}{\text{All positive cases on MRS}} \times 100$$

$$\text{Negative Predictive Value} = \frac{\text{TN}}{\text{All negative cases on MRS}} \times 100$$

$$\text{Diagnostic Accuracy} = \frac{\text{TP} + \text{TN}}{\text{TP} + \text{TN} + \text{FP} + \text{FN}} \times 100$$

## Results

Age range in this study was from 20-60 years with mean age of 49.31 ± 6.76 years. Majority of the patients 39 (35.45%) were between 41 to 50 years of age as shown in (Tab. 2). All the patients were

Age (years)	No. of Patients	%age
20-30	17	15.45
31-40	28	25.45
41-50	39	35.45
51-60	26	23.66
Total	110	100.0

Mean ± SD = 49.31 ± 6.76 years

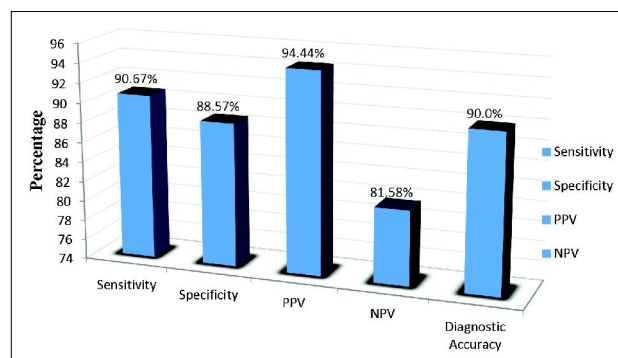
**Table 2:** %age of patients according to age distribution

subjected to magnetic resonance spectroscopy. MRS supported the diagnosis of malignant breast lesions in 72 (65.45%) patients. Histopathology confirmed malignancy in 75 (68.18%) cases where as 35 (31.82%) patients revealed benign breast lesion. In 72 MRS positive patients, 68 (True Positive) had malignant breast lesions and 04 (False Positive) had no malignancy on histopathology findings. Among, 38 MRS negative patients, 07 (False Negative) had malignant breast lesions on histopathology whereas 31 (True Negative) had benign lesions on histopathology as shown in (Tab. 3). Overall sensitivity, specificity, positive predictive value, negative predictive value and diagnostic accuracy of MRS in malignant breast lesions was 90.67%, 88.57%, 94.44%, 81.58% and 90.0% respectively (Fig. 4). Stratification of age groups has been shown in (Tab. 4-7).

	Positive result on MRS	Negative result on MRS	P-value
Positive Histopathology	68 (TP)*	07 (FN)***	0.668
Negative Histopathology	04 (FP)**	31 (TN)****	

\*-TP=True positive \*\*-FP=False positive \*\*\*-FN=False negative  
\*\*\*\*-TN=True negativ

**Table 3:** Summary of results



**Figure 1:** Diagnostic accuracy of Magnetic Resonance Spectroscopy in malignant breast lesions

	Positive result on MRS	Negative result on MRS	P-value
Positive Histopathology	09 (TP)	02 (FN)	0.486
Negative Histopathology	00 (FP)	06 (TN)	

Sensitivity: 81.82%, Specificity: 100.0%, Positive Predictive Value (PPV): 100.0%, Negative Predictive Value (NPV): 75.0%, Diagnostic Accuracy: 88.26%

**Table 4:** Stratification of age 20-30 years (n=17)

	Positive result on MRS	Negative result on MRS	P-value
Positive Histopathology	16 (TP)	01 (FN)	1.000
Negative Histopathology	01 (FP)	10 (TN)	

Sensitivity: 94.12%, Specificity: 90.91%, Positive Predictive Value (PPV): 94.12%, Negative Predictive Value (NPV): 90.91%, Diagnostic Accuracy: 92.86%

**Table 5:** Stratification of age 31-40 years (n=28)

	Positive result on MRS	Negative result on MRS	P-value
Positive Histopathology	23 (TP)	03 (FN)	0.812
Negative Histopathology	02 (FP)	11 (TN)	

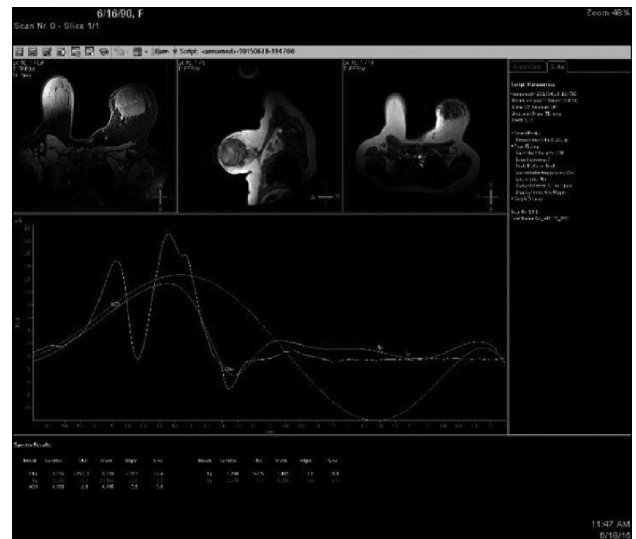
Sensitivity: 88.46%, Specificity: 84.62%, Positive Predictive Value (PPV): 92.0%, Negative Predictive Value (NPV): 78.57%, Diagnostic Accuracy: 87.18%

**Table 6:** Stratification of age 41-50 years (n=39)

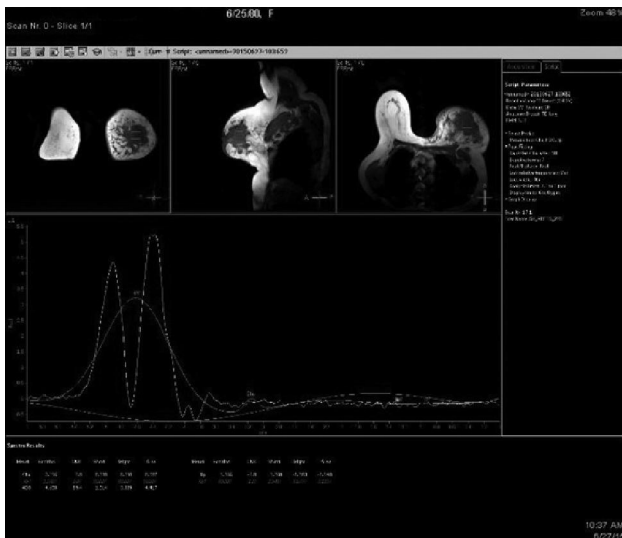
	Positive result on MRS	Negative result on MRS	P-value
Positive Histopathology	20 (TP)	01 (FN)	1.000
Negative Histopathology	01 (FP)	04 (TN)	

Sensitivity: 95.24%, Specificity: 80.0%, Positive Predictive Value (PPV): 95.24%, Negative Predictive Value (NPV): 80.0%, Diagnostic Accuracy: 92.31%

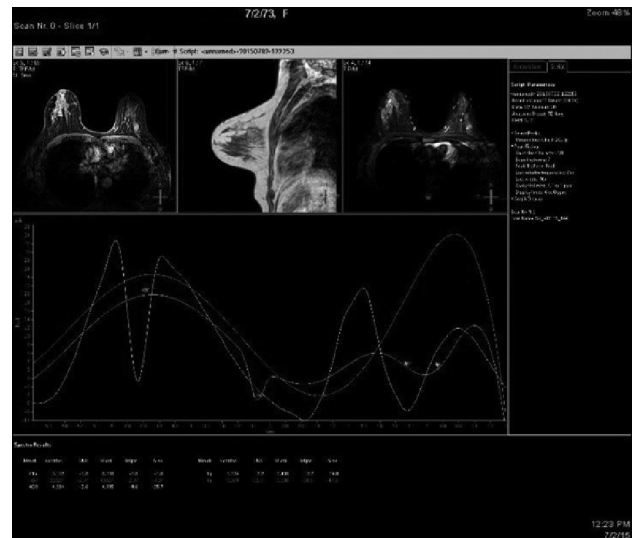
**Table 7:** Stratification of age 51-60 years (n=26)



**Figure 3:** MRS Breast Case 2 MR Spectroscopy showing raised choline / creatine ratio, greater than 1.5 suggestive of malignant etiology.



**Figure 2:** MRS Breast Case 1 MR Spectroscopy showing raised choline / creatine ratio, greater than 1.5 suggestive of malignant etiology



**Figure 4:** MRS Breast Case 3 MR Spectroscopy showing raised choline / creatine ratio, greater than 1.5 suggestive of malignant etiology.

## Discussion

Noninvasive diagnosis of breast cancer remains a major clinical problem. Mammography and sonography are currently the most sensitive modalities for detecting breast cancer. Most Chinese women have relatively small, dense breasts,<sup>12</sup> which is one of the various factors leading to false-negative findings on mammography.<sup>13</sup> Practically, sonography is chosen as the primary workup tool in the clinics. However, the sonographic features for benign and malignant lesions have been shown to override each other substantially.<sup>14,15</sup> These limitations of mammography and sonography and the great desire not to miss a malignant lesion in the early stage of disease lead to aggressive biopsy, but the biopsy rate for cancer is only 10% to 30%.<sup>16,17</sup> This means that 70% to 90% of breast biopsies are performed for benign diseases, which induce unnecessary patient discomfort and anxiety in addition to increasing costs to the patient. Clearly, there is a great need for development of additional reliable methods to complement the existing diagnostic procedures to avoid unnecessary biopsy.

High-resolution contrast-enhanced MRI has recently emerged as a sensitive imaging modality for the detection of breast cancer. The high sensitivity, which approaches 98%, makes MRI useful in specific clinical situations, such as evaluating patients with breast implants, detecting local recurrence after breast-conserving therapy, and detecting multifocal / multicentric disease. However, the moderately low specificity of 47 - 67% requires MRI-guided biopsy of lesions not seen on other imaging modalities, many of which are later found to be benign. Other adjunct imaging modalities that can better characterize the enhancing lesions on MRI are greatly needed. In vivo proton MR spectroscopy (1H-MRS) is a noninvasive technique that has great potential to provide tumor metabolism, which may be used in tumor diagnosis and evaluating the therapeutic response of the tumor.<sup>18-20</sup> Recently, breast 1H-MRS has been shown to improve cancer diagnosis based on elevated choline-containing compounds (tCho) metabolite peak. Several studies conducted at 1.5T have shown that in vivo 1H-MRS can be used to distinguish between benign and malignant tissues based on the hypothesis that tCho is only detectable in malignancies.<sup>18-20</sup>

In this study, we have determined the diagnostic accuracy of magnetic resonance spectroscopy (MRS) in malignant breast lesions, taking histopathology as gold standard. Age range in our study was from 20-60 years with mean age of  $49.31 \pm 6.76$  years. Majority of the patients 39 (35.45%) were between 41 to 50 years of age. The incidence rate of breast cancer increases with age, from 1.5 cases per 100,000 in women 20-24 years of age to a peak of 421.3 cases per 100,000 in women 75-79 years of age; 95% of new cases occur in women aged 40 years or older. The median age of women at the time of breast cancer diagnosis is 61 years.<sup>21</sup> Rates of in situ breast cancer stabilized among women 50 years and older in the late 1990s; this is consistent with the proposed effects of screening saturation. However, the incidence of in situ breast cancer continues to increase in younger women.<sup>21</sup>

In our study, Magnetic Resonance Spectroscopy supported the diagnosis of malignant breast lesions in 72 (65.45%) patients. Histopathology confirmed malignancy in 75 (68.18%) cases where as 35 (31.82%) patients revealed benign breast lesion. In 72 MRS positive patients, 68 (True Positive) had malignant breast lesions and 04 (False Positive) had no malignancy on histopathology findings. Among, 38 MRS negative patients, 07 (False Negative) had malignant breast lesions on histopathology whereas 31 (True Negative) had benign lesions on histopathology. So, overall sensitivity, specificity, positive predictive value, negative predictive value and diagnostic accuracy of MRS in malignant breast lesions was 90.67%, 88.57%, 94.44%, 81.58% and 90.0% respectively.

In a pooled analysis, it was shown that tCho detectability criterion could identify malignancies with 89% sensitivity and 87% specificity.<sup>18-20</sup> Baek HM, et al<sup>11</sup> in his study has found the sensitivity and specificity, of magnetic resonance spectroscopy in differentiating benign and malignant breast lesions as 66.0% and 92.0% respectively. While Begley JKP, et al<sup>10</sup> reported the sensitivity and specificity of MR Spectroscopy for diagnosing malignant breast lesions as 90% and 89% respectively. Recently, Haddadin IS, et al<sup>22</sup> reported 73% sensitivity and 77% specificity of magnetic resonance spectroscopy for distinguishing benign

from malignant lesions.

In a pooled analysis of nineteen studies, pooled sensitivity and specificity of magnetic resonance imaging in diagnosing breast cancer were 73% and 88% respectively. Katz-Brull R, et al<sup>23</sup> published a non-systematic review and meta-analysis of five clinical studies, examining the utility of MRS to distinguish benign and malignant breast lesions. In this meta-analysis, pooled results of five clinical studies from 153 lesions gave an estimated sensitivity for MRS of 83% [95% confidence interval (95% CI) 73% - 89%] and specificity of 85% (95% CI 71% - 93%) in the differentiation of benign and malignant breast lesions. The sensitivity and specificity of magnetic resonance spectroscopy in diagnosing malignant breast lesions was found to be 69.0% and 90.0% respectively by Meisamy S, et al.<sup>24</sup>

Sardanelli F, et al<sup>25</sup> in his study has shown the sensitivity and specificity of magnetic resonance spectroscopy in diagnosing malignant breast lesions as 90.0% and 92.0% respectively. On the other hand, Bartella L, et al<sup>26</sup> in his study reported this sensitivity and specificity of magnetic resonance spectroscopy in diagnosing malignant breast lesions as 100% and 88.0% respectively. The authors hypothesized that MRS would improve the positive predictive value of MRI of the breast and reported that the use of MRS as an adjunct to MRI would have significantly ( $P = 0.01$ ) increased the positive predictive value of biopsy from 35% (95% confidence interval: 21%, 52%) to 82% (95% confidence interval: 56%, 95%). In addition, they reported that if MRS had been used as an adjunct to MRI in 40 lesions of unknown histologic type, biopsy could have been spared in 23 lesions (58%), and none of the cancers would have been missed. Similarly, in a conference paper, Brennan S, et al<sup>27</sup> suggested that if MRS had been used, biopsy would have been spared in 59% with BI-RADS 4 lesions and in 87% with BI-RADS 4 lesions that were benign, without missing any cancers. So, our study concluded that Magnetic resonance spectroscopy (MRS) has revolutionized the diagnosis and management of malignant breast lesions. So, being non-invasive and a highly sensitive tool of investigation, it should be used for screening and accurate pre-operative identification of breast lesions in these particular

patients in order to reduce morbidity and mortality. Technical difficulties in breast MRS such as motion artifacts due to swallowing and breathing, contamination of the spectra by adjacent fat were potential limitations of our study.

## Conclusion

This study concluded that magnetic resonance spectroscopy (MRS) is a highly sensitive and accurate modality for diagnosing malignant breast lesions, and has not only dramatically improved our ability of diagnosing breast cancer but also improves patient care by accurate and timely diagnosis for taking proper treatment options for these particular patients. So, being non-invasive and a highly sensitive tool of investigation, we should recommend it as a primary screening tool for accurate screening and pre-operative identification of breast lesions in these particular patients in order to reduce morbidity and pure diagnostic biopsies in breast lesions which would consequently reduce complications of such procedures.

**Conflict of Interest:** None

## References

1. Buccimazza I. Approach to the diagnosis of a breast lump. *Continue Med Edu.* 2010; **23(11)**: 515-8.
2. Gotzsche PC, Nielsen M. Screening for breast cancer with mammography. *Cochrane Database Syst Rev.* 2011; **1**: 1877.
3. Sariego J. "Breast cancer in the young patient". *Am Surg.* 2010; **76(12)**: 1397-401.
4. Jemal A, Bray F, Centre MM, Ferlay J, Ward E, Forman D. Global cancer statistics. *Ca Cancer J Clin.* 2011; **61**: 69-90.
5. Jemal A, Center MM, Desantis C, Ward EM. Global patterns of cancer incidence and mortality rates and trends. *Cancer Epidemiol Biomarkers Prev.* 2010; **19**: 1893-907.

6. Turnbull LW. Dynamic contrast-enhanced MRI in the diagnosis and management of breast cancer. *NMR Biomed.* 2009; **22(1)**: 28-39.
7. Berg WA, Zhang Z, Lehrer D, Jong RA, Pisano ED, Barr RG, et al. Detection of breast cancer with addition of annual screening ultrasound or a single screening MRI to mammography in women with elevated breast cancer risk. *JAMA.* 2012; **307**: 1394-404.
8. Basara I, Orguc S, Coskun T. Single voxel in vivo proton magnetic resonance spectroscopy of breast lesions: experience in 77 cases. *Diagn Interv Radiol.* 2013; **19**: 221-26.
9. Shafqat G, Masror I, Rehan M, Afzal S. Dynamic contrast enhanced MRI breast for lesion detection and characterization with histopathological correlation: Preliminary experience at tertiary care hospital. *J Pak Med Assoc.* 2011; **61**: 252.
10. Begley JKP, Redpath TW, Bolan PJ, Gilbert FJ. In vivo proton magnetic resonance spectroscopy of breast cancer: a review of the literature. *Breast Cancer Res.* 2012; **14**: 207.
11. Baek HM. Diagnostic Value of Breast Proton Magnetic Resonance Spectroscopy at 1.5T in Different Histopathological Types. *SciWorld J.* 2012; **2012**: 1-8.
12. Maskarinec G, Meng L, Ursin G. Ethnic differences in mammographic densities. *Int J Epidemiol.* 2001; **30**: 959-65.
13. Saarenmaa I, Salminen T, Geiger U. The effect of age and density of the breast on the sensitivity of breast cancer diagnostic by mammography and ultrasonography. *Breast Cancer Res Treat.* 2001; **67**: 117-23.
14. Stavros AT, Thickman D, Rapp CL, Dennis MA, Parker SH, Sisney GA. Solid breast nodules: use of sonography to distinguish between benign and malignant lesions. *Radiology.* 1995; **196**: 123-34.
15. Jackson VP. The current role of ultrasonography in breast imaging. *Radiol Clin North Am.* 1995; **33**: 1161-170.
16. Duncan JL III, Cederbom GJ, Champaign JL. Benign diagnosis by image-guided core-needle breast biopsy. *Am Surg.* 2000; **66**: 5-10.
17. Chiou SY, Chou YH, Chiou HJM, et al. Sonographic features of nonpalpable breast cancer: a study based on ultrasound-guided wire-localized surgical biopsies. *Ultrasound Med Biol.* 2006; **32**: 1299-306.
18. Roebuck JR, Cecil KM, Schnall MD, Lenkinski RE. Human breast lesions: characterization with proton MR spectroscopy. *Radiol.* 1998; **209(1)**: 269-75.
19. Kvistad KA, Bakken IJ, Gribbestad IS. Characterization of neoplastic and normal human breast tissues with in vivo <sup>1</sup>H MR spectroscopy. *J Magnetic Resonance Imaging.* 1999; **10(2)**: 159-64.
20. Jagannathan NR, Kumar M, Seenu V. Evaluation of total choline from in-vivo volume localized proton MR spectroscopy and its response to neoadjuvant chemotherapy in locally advanced breast cancer. *Br J Cancer.* 2001; **84(8)**: 1016-22.
21. American Cancer Society. Breast Cancer Facts & Figures 2011-2012. Available at <http://www.cancer.org/Research/CancerFactsFigures/BreastCancerFactsFigures/breast-cancer-facts-and-figures-2011-2012>. Accessed June 10, 2013.
22. Haddadin IS, McIntosh A, Meisamy S. Metabolite quantification and high-field MRS in breast cancer. *NMR in Biomed.* 2009; **22(1)**: 65-76.
23. Katz-Brull R, Lavin PT, Lenkinski RE. Clinical utility of proton magnetic resonance spectroscopy in characterizing breast lesions. *J Natl Cancer Inst.* 2002; **94(16)**: 1197-203.
24. Meisamy S, Bolan PJ, Baker EH, Pollema MG, Le Chap T, Kelcz F, et al.. Adding in vivo quantitative <sup>1</sup>H MR spectroscopy to improve diagnostic accuracy of breast MR imaging: preliminary results of observer performance study at 4.0 T. *Radiology.*

---

2005; **236(2)**: 465-75.

25. Sardanelli F, Fausto A, Di Leo G, de Nijs R, Vorbuchner M, Podo F. In Vivo Proton MR Spectroscopy of the Breast Using the Total Choline Peak Integral as a Marker of Malignancy. *Am J Roentgenol.* 2009; **192**: 1608-17.
26. Bartella L, Morris EA, Dershaw DD, Liberman L, Thakur SB, Moskowitz C, et al. Proton MR spectroscopy with choline peak as malignancy marker improves positive predictive value for breast cancer diagnosis: preliminary study. *Radiology.* 2006; **239(3)**: 686-92.
27. Brennan S, Thakur SB, Liberman L, Wei H, Morris EA, Dershaw DD, et al. Proton Magnetic Resonance Spectroscopy in Breast Disease. Paper presented at the 94th Scientific Assembly and Annual Meeting of the Radiological Society of North America (RSNA) from [http://www.biowizard.com/cabs/mis\\_search.php?keyword=&author=&conference=:c95401&start=12/16/2007&end=1/16/2009](http://www.biowizard.com/cabs/mis_search.php?keyword=&author=&conference=:c95401&start=12/16/2007&end=1/16/2009)