

# DIAGNOSTIC ACCURACY OF NON INVASIVE IMAGING “SHEAR WAVE ELASTOGRAPHY” IN DETECTION AND STAGING OF LIVER FIBROSIS IN PATIENTS WITH VIRAL HEPATITIS BY TAKING HISTOPATHOLOGY AS GOLD STANDARD-EXPERIENCE AT TERTIARY CARE HOSPITAL OF SINDH

Ameet Jesrani,<sup>1</sup> Komal Parchani,<sup>1</sup> Marya Hameed<sup>2</sup>

1 Department of Radiology, Sindh Institute of Urology and Transplantation (SIUT), Karachi, Pakistan.

2 Department of Radiology, Jinnah Postgraduate Medical Center (JPMC), Karachi, Pakistan.

PJR January - March 2019; 29(1): 37-42

## ABSTRACT

**OBJECTIVE:** To evaluate the diagnostic accuracy of Elastography (shear wave) in detection and staging of liver fibrosis in patients with Chronic Hepatitis C by taking histopathology as gold standard. **DESIGN:** Cross sectional study. **PATIENTS AND METHODS:** 105 patients with chronic hepatitis C were studied including 44 female patients and 56 male patients on whom Shear Wave Elastography was performed. Elastography was performed, using curved transducer with ultrasound frequency of 3.5 MHz. The results of share wave elastography were compared with histopathology. All the information was recorded into predesigned proforma. **RESULTS:** Matching between the score of shear wave elastography and biopsy was moderate and considered as positive correlation between them. F0 accounted as lowest matching and F3 as highest matching. **CONCLUSION:** This non invasive technique (shear wave elastography) and liver biopsy show good matching and correlation with biopsy of liver in detection and staging of liver fibrosis. It is also very good technique in follow-up of progression of liver fibrosis. **Keywords:** Shear Wave Elastography, Non invasive imaging, Liver Fibrosis, Viral Hepatitis, Histopathology

## Introduction

Over 170 million people across the globe are affected by chronic hepatitis C.<sup>1</sup> The diagnosis and treatment of this disease in patients majorly banks on the staging of liver fibrosis. In case of moderate to severe (METAVIR stages F2 and F3) fibrosis, antiviral therapy is suggested.<sup>2</sup>

Biopsy of liver was recommended traditionally for diagnosis of liver fibrosis before treatment in patients with hepatitis C (chronic). But because of high cost, errors in sampling and variability in interobserver histopathological correlation, liver biopsy has its own limitations. Moreover, there remains a rare yet potential risk of life-threatening complications. Liver biopsy is

also not well accepted by patients and it is not appropriate for frequent evaluations. Furthermore, chronic hepatitis C makes the performance of liver biopsy impractical in patients who are candidates for antiviral therapy.<sup>3</sup> The shortcomings have created a need for alternative techniques, which are equally accurate and less injurious to eliminate the step of liver biopsy.

It is necessary to categorize the severity of fibrosis in patients with chronic liver disease for the proper treatment by antiviral drugs and surveillance. It is also helpful regarding prognosis of such patients. Since liver biopsy (LB) is an invasive procedure,

**Correspondence :** Dr. Ameet Jesrani  
Department of Radiology,  
Sindh Institute of Urology and Transplantation (SIUT),  
Karachi, Pakistan.  
Email: ameer.jesrani@yahoo.com

Submitted 10 January 2019, Accepted 12 February 2019

though has been the gold standard for long, it can cause complications like pain and bleeding.<sup>4,5</sup> So it is very crucial to introduce and apply non invasive procedure for categorization of liver fibrosis. Ultrasound elastography uses liver stiffness measurement (LSM) technique for categorization of liver fibrosis and thus is substitute for liver biopsy.<sup>6,7</sup> Asian-Pacific and European associations both have recommended the staging of liver fibrosis by non invasive ultrasound shear wave elastography technique.<sup>8</sup>

An ultrasound elastography technique called shear wave elastography (SWE) is easily available on ultrasound scanner and it can easily provide the map of stiffness of liver superimposed on B-mode image.<sup>9</sup> Liver stiffness can be measured on basis of estimation of shear wave velocity. With high accuracy of SWE it is clinically applicable to stage the fibrosis of liver.<sup>10,11</sup> Fibrosis of liver can be predicted by several inexpensive laboratory tests based non-invasive methods like the Fibrosis-4 index and aspartate amino-transferase-to-platelet index and these methods have been investigated for their diagnostic accuracy in evaluation of fibrosis of liver.<sup>12</sup>

Our study is meant to measure the diagnostic accuracy and clinical applicability of non-invasive imaging (shear wave elastography) in diagnosing and to stage fibrosis of liver in patients with hepatitis C (chronic) taking histopathological findings as gold standard.

## Material and Method

This cross-sectional study was conducted from February to August 2018 in Radiology department of Jinnah Postgraduate Medical Centre, Karachi from February to August 2018 after approval from ethical committee Total 107 patients of chronic hepatitis C were selected with patient's age ranging from 18 to 60 years. The mean age was  $35.5 \pm 10$  years of both genders. Cases were referred from outpatient department of liver clinics who were diagnosed as Hepatitis C positive by PCR method. Patients were selected prior to their interferon therapy. Full history, clinical examination and laboratory investigations (Complete blood count along with liver function tests) were carried out.

The patients who were unwilling for biopsy or referred to other hospital were excluded from the study.

Informed consent was taken from the research and ethical committee of the institution. Sample size was calculated considering both the sensitivity and specificity of shear wave elastography to diagnose liver fibrosis. Nonprobability consecutive sampling technique was applied to collect the samples. Scoring system (METAVIR) was used to evaluate and grade the fibrosis of liver which were graded as: F0 when there is no fibrosis; F1 when there is portal fibrosis without septa; F2 when there is portal fibrosis with rare septa; F3 when there are numerous septa without cirrhosis; and F4 when there is cirrhosis. The shear wave elastography imaging was done by consultant radiologists with more than 5 years experience. Commercially available ultrasound systems (TOSHIBA; GRE, Germany) with curved transducers having frequency of 3.5 MHz. After diagnosing liver cirrhosis, all patients were referred for biopsy of liver under ultrasound guidance. Biopsy was done by a 18 gauge true-cut needle and sample was sent for histopathological correlation.

Shear wave elastography findings were compared with histopathologically proven liver cirrhosis. Inclusion and exclusion criteria were strictly followed as to control the biasness and effect modifiers.

Statistical analysis was performed by using Statistical Package for Social Sciences (SPSS 21.0) as to obtain sensitivity and specificity of shear wave elastography in the diagnosis of liver cirrhosis and taken histopathology as gold standard. Frequency and percentage was calculated for qualitative variables, i.e, presenting complains, detailed history of presenting complains; shear wave elastography findings and histopathological findings.

Mean  $\pm$  SD was computed for quantitative variable, i.e. age of the patient. Taken histopathological findings as gold standard, all statistical parameters, (sensitivity, specificity, positive predictive value, negative predictive value) were calculated to obtain diagnostic accuracy of shear wave elastography.

## Results

This study includes 107 patients based on inclusion criteria. 65.7% of cases were graded as F2 which indicates significant fibrosis, 38% of cases were graded as F3 which indicates severe fibrosis and

17% of cases were graded as F4 which indicates cirrhosis. (Tab. 1: shows total number of cases and percentage of fibrosis).

F0	10 (9.3)
F1	26 (24.2)
F2	30 (28.0)
F3	22 (20.6)
F4	19 (17.8)

**Table 1:** Metavir fibrosis stage; n (%)

The median values, Interquartile ranges and *p* values of the measurements obtained for each fibrosis stage with shear wave elastography are summarized in (Tab. 2).

	METAVIR stage				
	F0	F1	F2	F3	F4
Median value, kPa	7.2	9.2	11.1	14.2	23.7
IQR	6.0-8.0	7.3-10.8	8.2-14.3	10.7-21.6	19.6-31.8
Range	5.1-8.8	5.4-25.8	6.0-34.0	8.5-33.3	11.1-55.0
<i>p</i> value		0.009	0.045	0.030	<0.001

**Table 2:** Median value, IQR, range and *p* value of liver stiffness measurements obtained with shear wave elastography for each fibrosis stage

Liver stiffness measurements by shear wave elastography, show higher median values for patients with given fibrosis stage as compared to those with less fibrosis (all *p* values < 0.05).

10.6 kPa was the optimal cutoff value for prediction of significant fibrosis, 13.2 kPa for severe fibrosis and 17.6 kPa for cirrhosis. (Tab. 3) summarizes the specificity, sensitivity, NPV, PPV for each METAVIR stage and we have found more than 80% specificity for all three stages in assessing fibrosis of liver.

Parameter	Stage ≥F2	Stage ≥F3	Stage ≥F4
Cutoff, kPa	10.6	13.2	17.6
Sensitivity, %	76.8 (65.1-86.1)	72.5 (56.1-85.4)	88.9 (65.3-98.6)
Specificity, %	83.3 (67.2-93.6)	84.6 (73.5-92.4)	88.5 (79.9-94.3)
PPV, %	89.8 (79.1-96.2)	74.4 (57.6-87.1)	61.5 (40.1-80.1)
NPV, %	65.2 (49.8-78.6)	83.3 (72.1-91.4)	97.5 (91.2-99.7)

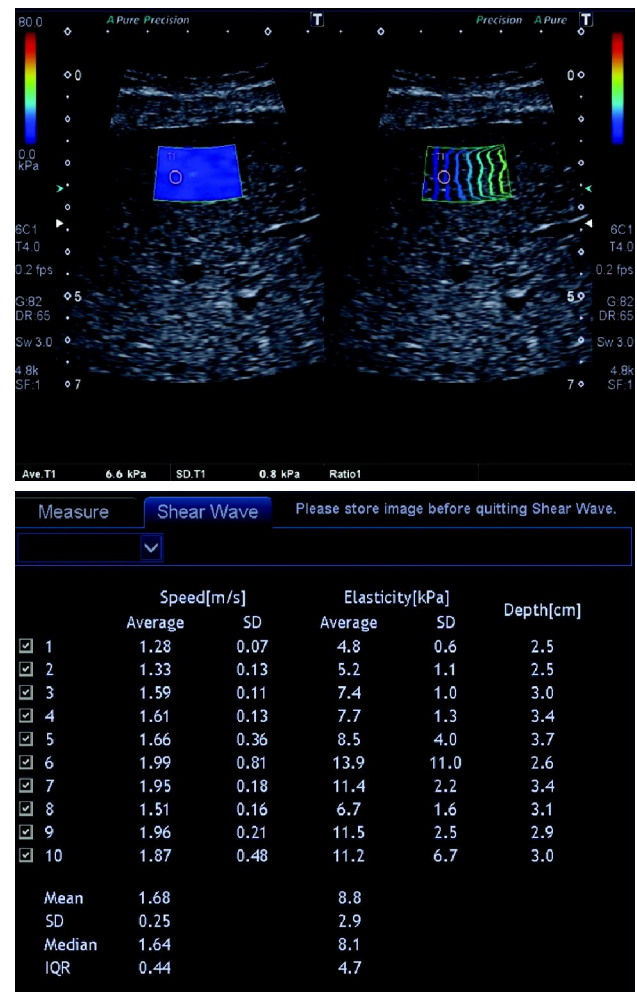
**Table 3:** Performance characteristics of 2-D shear wave elastography for staging liver fibrosis in patients with chronic liver diseases

(Tab. 4) summarizes the relation of concordance rates of liver stiffness measurements among METAVIR staging and shear wave elastography. Overall 56.2%

of cases (61 of 107) were accurately categorized by shear wave elastography. The F0-1 and the F4 staged cases show accuracy of more than 60% while F2 and F3 staged cases show comparatively lesser accuracy of correct classification of less than 50% on shear wave elastography. (Fig. 1) shows case of liver fibrosis (stage F0-F1)

Liver stiffness measurement	METAVIR stage					Concordance rate (%)
	F0-F1	F2	F3	F4	Total	
F0-F1, ≤10.6 kPa	30	12	4	0	46	65.2
F2, >10.6 to ≤13.2 kPa	4	7	6	1	18	38.9
F3, >13.2 to ≤17.6 kPa	0	8	6	1	15	40.0
F4, >17.6 kPa	2	2	6	16	26	61.5
Cumulative concordance						56.2

**Table 4:** Analysis of concordance of liver stiffness measurements obtained using shear wave elastography versus the METAVIR stage



**Figure 1:** Shows case of liver fibrosis, mean kPa of 8.8 (METAVIR stage F0-F1)

## Discussion

To expand liver disease, liver inflammation and fibrosis are considered as predominant pathologic processes. Various invasive and noninvasive tools are available for staging of liver fibrosis, Among noninvasive ones liver ultrasound elastography has considered as a crucial tool to stage fibrosis of liver.<sup>13</sup> As liver is encapsulated by firm envelope named as Glisson's capsule, so any changes like inflammation, edema, congestion and fatty changes, can raise the measurements and expand its stiffness, even in absence of fibrosis.<sup>7</sup> The study which we have designed has significant higher median liver stiffness measurements (LSMs) as compared to previous study for each stage of fibrosis in patients with chronic liver disease.<sup>14</sup> The median LSM for F0 was 7.2 kPa in this study while previous study show 5.7 kPa for F0 and 6.7 kPa for F1.<sup>14</sup> So our study show higher liver stiffness measurement in case of F0 stage than that of the foregoing study for F0 and F1 cases.<sup>14</sup>

For assessment of liver fibrosis, the ultrasound elastography has recently acknowledged as authentic method.<sup>15-18</sup> The shear wave examinations were effective in all cases in this study. The outcome shows that shear wave elastography yields very good results in patients with chronic hepatitis. The outcomes of study concerning the achievement rate of shear wave elastography measurements in patients with chronic hepatitis were indistinguishable results revealed in preceding studies utilizing shear wave elastography in patients.

To evaluate significant fibrosis, severe fibrosis and cirrhosis the ideal cutoff values were 10.6, 13.2 and 17.6 kPa, respectively. The ideal cutoff values for foreseeing each stage of fibrosis have not yet been initiated.<sup>19</sup> The optimal cutoff value was 7.2 kPa for estimation of significant fibrosis, 9.1 kPa for severe fibrosis and 11.7 kPa for cirrhosis in patients with hepatitis B (chronic). The optimal cutoff value was 7.1 kPa for estimation of significant fibrosis, 8.7 kPa for severe fibrosis and 10.4 kPa for cirrhosis in patients with chronic hepatitis C.<sup>20, 21</sup>

In our study with a cutoff of 10.6 kPa on shear wave elastography, the significant fibrosis showed high PPV (89.8%). The clinical efficacy of shear wave elastography increases at high PPV of LSMs for confirming significant fibrosis. Progression in liver

disease with indication for start of treatment was indicated by F2 stage. We have set up the indication of fibrosis in patients by using shear wave elastography with a cutoff of 17.6 kPa and negative predictive value was 97.5% for evaluation of cirrhosis and was very high for evaluating cirrhosis. So high negative predictive value in liver stiffness measurements recommends that shear wave elastography could be compelling for excluding cirrhosis in any case. A low NPV propose that shear wave elastography could be unsatisfactory for excluding significant fibrosis, and a low PPV recommends that shear wave elastography could be lacking for confirming cirrhosis. In addition, the concordance rate was low at 56.2% for shear wave elastography versus METAVIR stage. In this way, it is estimated that shear wave elastography is convenient for anticipating F2, F3 and F4 stages as significant fibrosis, severe fibrosis and cirrhosis respectively.

## Conclusion


We have found that shear wave elastography has a promising diagnostic role for liver fibrosis evaluation and its staging in patients with chronic hepatitis C. It is a convenient and cost effective modality that can effectively diagnose liver fibrosis and possibly further diagnostic method will not be required. Diagnosis of liver fibrosis can be made with certainty, so that subsequent management can be planned easily and it provides cost saving for the hospital as well.

**Conflicts of Interest:** There were no conflicts of interests among authors

## References

1. Yuan H, Lee W. Nonresponse to treatment for hepatitis C: current management strategies. *Drugs* 2008; **68**: 27-42.
2. Bedossa P, Poinard T for the METAVIR cooperative study group. An algorithm for the grading of activity in chronic hepatitis C. The METAVIR Cooperative Study Group. *Hepatology* 1996; **24**: 289-93.

3. Trifan Anca, Stanciu Carol. Checkmate to liver biopsy in chronic hepatitis C? *World J Gastroenterol* 2012 October 21; **18(39)**: 5514-20.
4. Bravo, A.A., Sheth, S.G., and Chopra, S. Liver biopsy. *N Engl J Med*. 2001; **344**: 495-500.
5. Cadranel, J.F., Rufat, P., and Degos, F. Practices of liver biopsy in France: Results of a prospective nationwide survey. For the Group of Epidemiology of the French Association for the Study of the Liver (AFEF). *Hepatology*. 2000; **32**: 477-81.
6. Cosgrove, D., Piscaglia, F., Bamber, J., Bojunga, J., Correas, J.M., Gilja, O.H. et al. EFSUMB guidelines and recommendations on the clinical use of ultrasound elastography: Part 2. Clinical applications. *Ultraschall Med*. 2013; **34**: 238-53.
7. Ferraioli, G., Filice, C., Castera, L., Choi, B.I., Sporea, I., Wilson, S.R., et al. WFUMB guidelines and recommendations for clinical use of ultrasound elastography: Part 3. Liver. *Ultrasound Med Biol*. 2015; **41**: 1161-79.
8. Sarin, S.K., Kumar, M., Lau, G.K., Abbas, Z., Chan, H.L., Chen, C.J., Chen, D.S., et al. Asian-Pacific clinical practice guidelines on the management of hepatitis B: A 2015 update. *Hepatology Int*. 2016; **10**: 1-98.
9. Shiina, T., Nightingale, K.R., Palmeri, M.L., Hall, T.J., Bamber, J.C., Barr, R.G., et al. WFUMB guidelines and recommendations for clinical use of ultrasound elastography: Part 1. Basic principles and terminology. *Ultrasound Med Biol*. 2015; **41**: 1126-47.
10. Jiang, T., Tian, G., Zhao, Q., Kong, D., Cheng, C., Zhong, L., et al. Diagnostic accuracy of 2-D-shear wave elastography for liver fibrosis severity: A meta-analysis. (e0157219) *PLoS ONE*. 2016; **11**
11. Li, C., Zhang, C., Li, J., Huo, H., and Song, D. Diagnostic accuracy of real-time shear wave elastography for staging of liver fibrosis: A meta-analysis. *Med Sci Monit*. 2016; **22**: 1349-59.
12. Xiao, G., Yang, J., and Yan, L. Comparison of diagnostic accuracy of aspartate aminotransferase to platelet ratio index and Fibrosis-4 index for detecting liver fibrosis in adult patients with chronic hepatitis B virus infection: A systemic review and meta-analysis. *Hepatology*. 2015; **61**: 292-302.
13. Barr, R.G., Ferraioli, G., Palmeri, M.L., Goodman, Z.D., Garcia-Tsao, G., Rubin, J., et al. Elastography assessment of liver fibrosis: Society of radiologists in ultrasound consensus conference statement. *Radiology*. 2015; **276**: 845-61.
14. Zheng, J., Guo, H., Zeng, J., Huang, Z., Zheng, B., Ren, J., et al. Two-dimensional shear-wave elastography and conventional US: The optimal evaluation of liver fibrosis and cirrhosis. *Radiology*. 2015; **275**: 290-300.
15. Cassinotto, C., Boursier, J., de Lédinghen, V., Lebigot, J., Lapuyade, B., Cales, P., et al. Liver stiffness in nonalcoholic fatty liver disease: A comparison of supersonic shear imaging, FibroScan, and ARFI with liver biopsy. *Hepatology*. 2016; **63**: 1817-27.
16. Gerber, L., Kasper, D., Fitting, D., Knop, V., Vermehren, A., Sprinzl, K., et al. Assessment of liver fibrosis with 2-D shear wave elastography in comparison to transient elastography and acoustic radiation force impulse imaging in patients with chronic liver disease. *Ultrasound Med Biol*. 2015; **41**: 2350-59.
17. Samir, A.E., Dhyani, M., Vij, A., Bhan, A.K., Halpern, E.F., Méndez-Navarro, J., et al. Shear-wave elastography for the estimation of liver fibrosis in chronic liver disease: Determining accuracy and ideal site for measurement. *Radiology*. 2015; **274**: 888-96.
18. Zhuang, Y., Ding, H., Zhang, Y., Sun, H., Xu, C., and Wang, W. Two-dimensional shear-wave elastography performance in the noninvasive evaluation of liver fibrosis in patients with chronic hepatitis B: Comparison with serum fibrosis indexes. *Radiology*. 2017; **283**: 873-82.

- 
- 
19. Lupsor-Platon, M., Badea, R., Gersak, M., Maniu, A., Rusu, I., Suci, A., et al. Noninvasive assessment of liver diseases using 2-D shear wave elastography. *J Gastrointest Liver Dis.* 2016; **25**: 525-32.
  20. Ferraioli, G., Tinelli, C., Dal Bello, B., Zicchetti, M., Filice, G., Filice, C., and Liver Fibrosis Study Group. Accuracy of real-time shear wave elastography for assessing liver fibrosis in chronic hepatitis C: A pilot study. *Hepatology.* 2012; **56**: 2125-2133
  21. Zeng, J., Liu, G.J., Huang, Z.P., Zheng, J., Wu, T., Zheng, R.Q., and Lu, M.D. Diagnostic accuracy of two-dimensional shear wave elastography for the non-invasive staging of hepatic fibrosis in chronic hepatitis B: A cohort study with internal validation. *Eur Radiol.* 2014; **24**: 2572-81.