

# DIAGNOSTIC ACCURACY OF TISSUE HARMONIC IMAGING IN DETECTION OF APPENDICITIS BY TAKING HISTOPATHOLOGY AS GOLD STANDARD-EXPERIENCE AT TERTIARY CARE HOSPITAL

Talha Yaseen,<sup>1</sup> Ameet Jesrani,<sup>2</sup> Sehrish Mahreen,<sup>2</sup> Rizwan Ajmal<sup>1</sup>

1 Department of Radiology, Liaquat National Hospital, Karachi, Pakistan.

2 Department of Radiology, Sindh Institute of Urology and Transplantation (SIUT), Karachi, Pakistan.

PJR January - March 2019; 29(1): 14-19

## ABSTRACT

**OBJECTIVE:** To determine the diagnostic accuracy of tissue harmonic imaging in detection of appendicitis by taking histopathology as gold standard. **DESIGN:** Cross sectional study. **PATIENTS AND METHODS:** There were 378 patients with sign and symptoms of appendicitis patients were included in this study. Ultrasonography was performed, using linear and curved transducers with ultrasound frequencies ranged between 2.5 and 7.5 MHz, commercially available ultrasound systems. The examination was performed with both Conventional and Tissue Harmonic Image. Specimen for the confirmation of appendicitis was taken during surgery and sent to Histopathology Lab. All the information was recorded into predesigned proforma. **RESULTS:** Sensitivity, specificity, PPV, NPV and accuracy of tissue harmonic imaging in detection of appendicitis was 81.18%, 86.88%, 42.86%, 97.44% and 86.26% respectively. **CONCLUSION:** We conclude that tissue harmonic imaging better visualizes the appendix and should be the preferred modality for scanning the right lower abdomen in cases of suspected acute appendicitis.

**Keywords:** Acute appendicitis, Harmonic imaging, Ultrasound modality

## Introduction

The incidence of appendicitis is about 2-4 per 1000 children. Appendicitis is the commonest cause of acute abdominal pain that requires prompt surgery.<sup>1</sup> Appendicitis is usually diagnosed clinically because of its common occurrence as a surgical emergency. Usual presentation of patients with acute appendicitis is crampy pain in right iliac fossa or around umbilicus, associated with nausea; vomiting. On clinical examination point tenderness in the right lower quadrant along with rebound tenderness usually present, and there is leukocytosis with a left shift.<sup>2</sup> Several imaging modalities are available to diagnose suspected appendicitis so that negative appendectomy should not be performed.<sup>3</sup>

It is sometimes difficult to visualize normal appendix

on gray-scale ultrasound. However, harmonic imaging (HI) gives better visualization on abdominal ultrasound because of high contrast and spatial resolution resulting in least artifact on imaging.<sup>4</sup> Harmonic imaging (HI) is a relatively new technique in ultrasonography. Initially it was used only in obese adult patients. It provides better diagnosis of acute appendicitis and thus subsequent management can be planned.

Conventional ultrasonography is usually compromised by artifacts like refraction and shadowing. Tissue harmonic imaging is a new sonographic technique in which the waves are produced from nonlinear interaction of the transmitted frequencies as these pass through the body tissues. Echoes are transmitted and received at the same frequency in conventional

**Correspondence :** Dr. Ameet Jesrani  
Department of Radiology  
Sindh Institute of Urology and Transplantation (SIUT),  
Karachi, Pakistan.  
Email: ameer.jesrani@yahoo.com

Submitted 7 January 2019, Accepted 12 February 2019

ultrasound while in harmonic sonography only the second harmonic frequency is used for imaging. In harmonic imaging, tissue itself generate harmonic band having the scattered and distorted energy weaker than the energy transmitted and thus, produce weaker harmonics. This is the reason, tissue harmonic sonography results in improved signal to noise ratio by significantly decreasing noise and gives clear artifact free images as compared to conventional sonography.<sup>5</sup>

A study was done which revealed diagnosis of inflamed appendix on tissue harmonic imaging and conventional sonography as 93% and 86% respectively.<sup>1</sup>

Ultrasound has a vital role in imaging pediatric age group patients because of its availability and non hazardous side effects like irradiations.<sup>6</sup> Because of increasing efficacy of ultrasound in diagnosing appendicitis, use of computed tomography for diagnosis as a routine imaging modality has been declining and saving children from exposure to ionizing radiations.<sup>1,7</sup> Another study was performed which revealed 2.85% sensitivity and 87.5% specificity of ultrasound in diagnosing appendicitis and 7% incidence of the disease.<sup>8</sup>

The purpose of our study is to evaluate the accuracy of tissue harmonic imaging in diagnosing appendicitis because of its better contrast and resolution which gives clear image as compared to conventional sonography.

## Material and Methods

This cross-sectional study was conducted from January 2015 to January 2018 in Radiology department of Liaquat National Hospital, Karachi. The study was approved by Institutional Ethical Review Board. Total 786 patients were selected with age 01 to 12 years of both gender referred from emergency with complain of crampy pain around umbilicus or right iliac fossa, nausea and vomiting, point tenderness in the right lower quadrant, rebound tenderness, and leukocytosis (TLC>11000).

The patients who were unwilling for surgery, referred to other hospital or diagnosed with other disease were excluded from the study. Informed consent was taken from the research and ethical committee of the

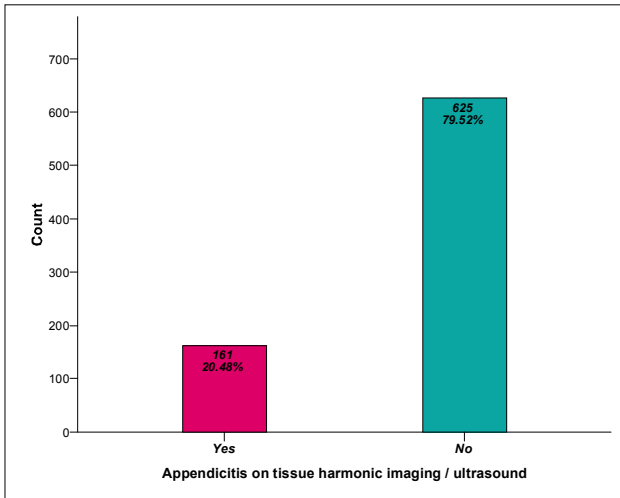
institution. Sample size was calculated considering both the sensitivity and specificity of tissue harmonic imaging to diagnose appendicitis. Nonprobability consecutive sampling technique was applied to collect the samples. Both the conventional and tissue harmonic imaging examinations were performed on same patient with suspected appendicitis by Consultant Radiologists with more than 5 years experience. Commercially available ultrasound systems (TOSHIBA; GRE, Germany) were used with both linear and curved transducers having frequencies ranged between 2.5 and 7.5 MHz. There were optimized scanning parameters for each method and same focal zone was used to obtain all images. Identical images were taken in two standard planes, transverse and longitudinal by using cine playback mode. Harmonic images were taken at 2.0 MHz transmitted frequency and 4.0 MHz receiving harmonic bandwidth. Images in conventional ultrasound were taken at 3.5 MHz. After diagnosing appendicitis, all patients were referred for surgery. Sonographic findings of both the performed techniques were compared with histopathologically proven appendicitis. Inclusion and exclusion criteria was strictly followed as to control the biasness and effect modifiers.

Statistical analysis was performed by using Statistical Package for Social Sciences (SPSS 21.0) as to obtain sensitivity and specificity of tissue harmonic imaging in the diagnosis of appendicitis and taken histopathology as gold standard. Frequency and percentage was calculated for qualitative variables, i.e, presenting complains, detailed history of presenting complains, tissue harmonic imaging findings and surgical findings. Mean  $\pm$  SD was computed for quantitative variable, i.e. Age of the patient. Taken histopathological findings as gold standard, all statistical parameters, (sensitivity, specificity, positive predictive value, negative predictive value) were calculated to obtain diagnostic accuracy of tissue harmonic imaging.

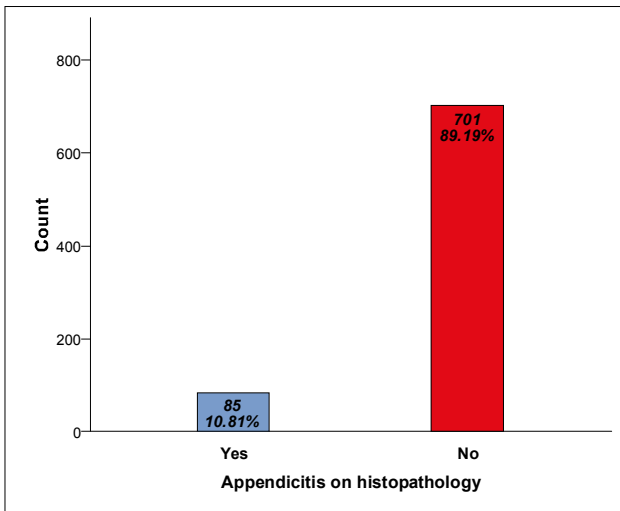
## Results

786 patients with suspected appendicitis were included in the study. Mean age of the patients was  $6.12 \pm 2.70$ . Both genders were included in which 52.04% (409/786) were male and 47.96% (377/786) were female. 20.48% (161/786) patients were diagnosed

appendicitis by tissue harmonic imaging and 10.81% diagnosed by histopathology as shown in (Graph 1 and 2) respectively.



**Graph 1:** Finding of tissue harmonic ultrasound, n=786



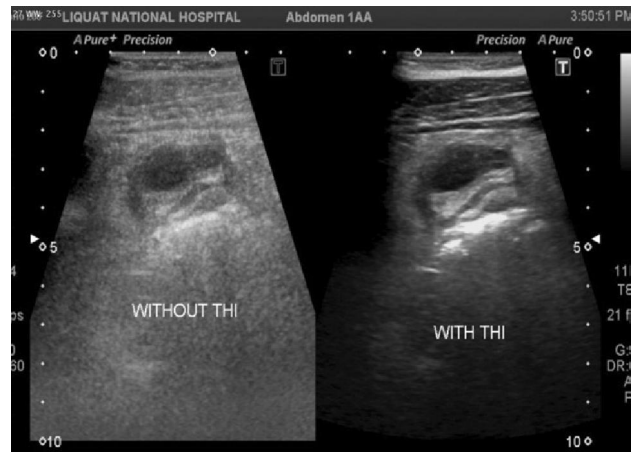**Graph 2:** Finding of histopathology, n = 786

Accuracy of tissue harmonic imaging in diagnosing appendicitis is tabulated in (Tab. 1), and (Fig. 1 and 2) shows the better visualization of inflamed appendix on Tissue Harmonic imaging as compared to Conventional Ultrasound imaging. Sensitivity, specificity, PPV, NPV and accuracy of tissue harmonic imaging in detection of appendicitis was 81.18%, 86.88%, 42.86%, 97.44% and 86.26% respectively.

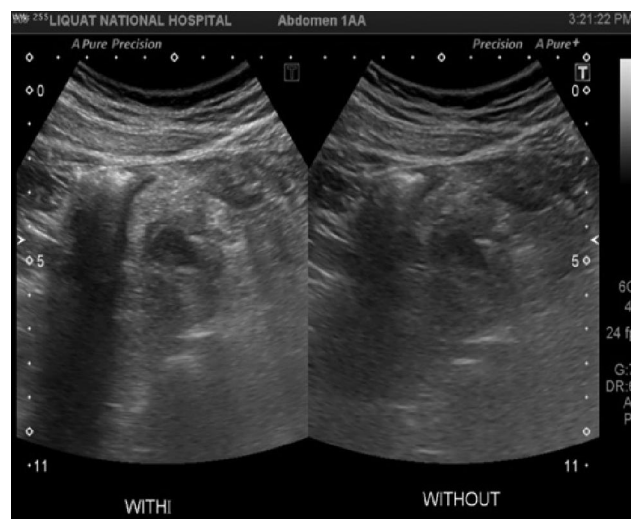
Tissue harmonic U/S diagnosis of appendicitis	Histopathology Proven Appendicitis		Total
	Positive	Negative	
Positive	69 (TP)	92 (FP)	161 (20.5%)
Negative	16 (FN)	609 (TN)	625 (79.5%)
Total	85 (10.8%)	701 (89.2%)	786

Statistics	Estimate
Sensitivity	81.18%
Specificity	86.88%
Positive Predictive Value	42.86%
Negative Predictive Value	97.44%
Diagnostic Accuracy	86.26%

**Table 1:** Diagnostic accuracy of tissue harmonic imaging in detection of appendicitis



**Figure 1:** Better visualization of appendicitis on ultrasound with Tissue Harmonic imaging as compared to ultrasound without Tissue Harmonic imaging



**Figure 2:** Better visualization of appendicitis on ultrasound with Tissue Harmonic imaging as compared to ultrasound without Tissue Harmonic imaging

## Discussion

Definite clinical diagnosis is the basis in clinical practice. Many treatment options are available once the definite diagnosis is made. A single diagnostic test with certainty does not exist for appendicitis.<sup>9,10</sup> Acute appendicitis is the commonest surgical condition that needs urgent intervention,<sup>11</sup> approximately 7% of the total population undergoes appendectomy.<sup>12</sup> In 30-45% cases there is nonspecific clinic approach.<sup>13</sup> Despite of the uncertain diagnosis, appendicitis needs urgent management so that the disease should not progress due to misdiagnosis as it carries high risk of complications like perforation which occurs in about one third of the patients.<sup>14,15</sup> In case of atypical acute appendicitis, immediate or delayed surgery depends on surgeon. Abdominal ultrasound can aid in the diagnosis of appendicitis and subsequent management by the surgeons. Blab et al.<sup>16</sup> stated that high certainty in the diagnosis can only be possible by combining all diagnostic parameters and investigations.

In our study total 786 patients were included with their ages from 1-12 years. Mean age was  $6.12 \pm 2.70$ . In few of the international studies, it is concluded that the peak incidence is between 6 and 30 years.<sup>17,18</sup> In our 786 cases, 52.04% (409/786) were male and 47.96% (377/786) were females. Oliver et al reported, total 50 patients for their prospective study. Mean age of patients was 9.9 years (range 2-17 years), and there were equal numbers of both genders.<sup>1</sup>

Ultrasound has many advantages in the diagnosis of Acute Appendicitis which includes its low cost, no irradiation, and it's a dynamic study which allows the operator to carefully examine the area of interest with different views again and again. Meanwhile it has ultrasound has some limitations that it is operator dependence procedure and not so much sensitive in overweight patients.<sup>19,20,21</sup> Ultrasound for appendicitis performed by a well experienced operator with high proficiency equipment like high resolution transducer, have a sensitivity and specificity of about 90%. Ultrasound can also accurately diagnose 70 to 80% of the patients having appendicitis like symptoms.<sup>22</sup> In our conducted study, ultrasound was done by consultant radiologists who have more than 5 years experience. Harmonic imaging is a new ultrasound modality in which the waves are produced from nonlinear dis-

tortion of ultrasound waves in the body tissues.

Tissue harmonic imaging (HI) has high contrast and spatial resolution which gives in artifact free images, and hence shown to improve abdominal ultrasound significantly. We have found higher image quality of inflamed appendix in our patients done with harmonic imaging. With harmonic imaging, not only the global image quality is improved but overall associated parameters and surrounding tissues were also visualized. 20.48% (161/786) cases were diagnosed as appendicitis in our study by harmonic imaging with sensitivity 81.18%, Specificity 86.88%, PPV 42.86%, NPV 97.44% and 86.26% accuracy. Hagendorf et al.<sup>23</sup> stated the potential of harmonic imaging to lessen appendix perforation. Almost same results were given by Henn et al and Shaprio et al describing that appendix is better visualized by tissue harmonic imaging and its success rate is also higher in histopathologically proven appendicitis.<sup>24,25</sup> Our study confirms that most accurate diagnosis of appendicitis can be achieved by modern devices operated by an experienced hand. There was lower sensitivity of the method as compared to the specificity due to some unrestrained factors (obesity, nonspecific localization of appendix and associated diseases) which revealed false negative results.

## Conclusion

We have found that tissue harmonic imaging can better visualize appendix and its surrounding tissues, and should be a preferred modality in the assessment of acute appendicitis. It is a convenient and cost effective modality that can effectively diagnose appendicitis and possibly further diagnostic method will not be required. Diagnosis of appendicitis can be made with certainty, so that subsequent management can be planned easily to avoid negative appendectomy and provides cost saving for the hospital as well.

## References

1. Rompel O, Huelse B, Bodenschatz K, Reutter G, Darge K. Harmonic US imaging of appendicitis in children. *Pediatr Radiol*. 2006; **36**: 1257-64.

2. Fonio P, Coppolino F, Russo A, Andrea AD, Giannattasio A, Reginelli A, et al. Ultrasonography (US) in the assessment of pediatric non traumatic gastrointestinal emergencies. *Crit Ultrasound J*. 2013; **5(1)**: 12.
3. Parks NA, Schroepel TJ. Update on imaging for acute appendicitis. *Surg Clin North Am*. 2011; **91(1)**: 141-54.
4. Zakaria O, Sultan TA, Khalil TH, Wahba T. Role of clinical judgment and tissue harmonic imaging ultrasonography in diagnosis of paediatric acute appendicitis. *World J Emerg Surg*. 2011; **6**: 39.
5. Oktar SO, Yücel C, Özdemir H, Ulutürk A, Isik S. Comparison of conventional sonography, real-time compound sonography, tissue harmonic sonography, and tissue harmonic compound sonography of abdominal and pelvic lesions. *Am J Radiol*. 2003; **181**: 1341-7.
6. Dumitriu D, Galloy MG, Claudon M. New techniques in pediatric ultrasound. *Ultrasound Clin*. 2010; **(5)**: 153-69.
7. Qazi AS. Sonographic accuracy in determining acute appendicitis in the children in a tertiary care hospital. *Ann King Edward Med Coll*. 2008; **14(4)**: 133-7.
8. Arooj S, Mansoor M, Amir I. Ultrasound for the diagnosis of acute appendicitis: a hospital based study. *Pak J Med Health Sci*. 2013; **7(4)**: 59.
9. Zakaria OM, Adly OA, El-Labban GA, Khalil HT. Acute appendicitis in children: a clinical practice guideline scoring system. *Suez Canal Univ Med J*. 2005; **8**: 20-6.
10. Samuel M. Pediatric appendicitis score. *J Pediatr Surg*. 2002; **37**: 877-81.
11. Liu CD, McFadden DW. Acute abdomen and appendix. In: Greenfield LJ, editors. *Surgery: scientific principles and practice*. Philadelphia: Lippincott-Raven; 1997. P. 1246-61.
12. Addiss DG, Shaffer N, Fowler BS. The epidemiology of appendicitis and appendectomy in the United States. *Am J Epidemiol*. 1990; **132**: 910-25.
13. Telford GL, Condon RE. Appendix. In: Zuidema GD, *Surgery of the alimentary tract*. Philadelphia: Saunders; 1991. P. 133-41.
14. Flum DR, Koepsell T. The clinical and economic correlates of misdiagnosed appendicitis: Nationwide analysis. *Arch Surg* 2002; **137**: 799-804.
15. Putnam TC, Gagliano N, Emmens RW. Appendicitis in children. *Surg Gynecol Obstet*. 1990; **170**: 527-32.
16. Blab E, Kohlhuber U, Tillawi S. Advancements in the diagnosis of acute appendicitis in children and adolescents. *Eur J Pediatr Surg*. 2004; **14**: 404-9.
17. Schwartz SI. Appendix. In: Schwartz SI, editor. *Principles of surgery*. New York: McGraw Hill; 1994. P. 1307-18.
18. Puig S, Hormann M, Rebhandl W, Felder-Puig RF, Prokop M, Paya K. US as a primary diagnostic tool in relation to negative appendectomy: six years experience. *Radiology*. 2003; **226**: 101-4.
19. Rao PM, Rhea JT, Novelline RA. Helical CT technique for the diagnosis of appendicitis: prospective evaluation of a focused appendix CT examination. *Radiology*. 1997; **202**: 139.
20. Orr RK, Porter D, Hartman D. Ultrasonography to evaluate adults for appendicitis: decision making based on metaanalysis and probabilistic reasoning. *Acad Emerg Med*. 1995; **2**: 644-50.
21. Rao PM, Feltmate CM, Rhea JT, Schulick AH, Novelline RA. Helical computed tomography in differentiating appendicitis and acute gynecologic conditions. *Obstet Gynecol*. 1999; **93**: 417-21.
22. Gaensler EH, Jeffrey RB Jr, Laing FC, Townsend RR. Sonography in patients with suspected acute

- 
- appendicitis: value in establishing alternative diagnoses. *AJR Am J Roentgenol.* 1989; **152**: 49-51.
23. Hagendorf BA, Clarke JR, Burd RS. The optimal initial management of children with suspected appendicitis: a decision analysis. *J Pediatr Surg.* 2004; **39**: 880-5.
24. Shapiro RS, Wagreish J, Parsons RB, Stancato-Pasik A, Yeh HC, Lao R. Tissue harmonic imaging sonography: evaluation of image quality compared with conventional sonography. *AJR.* 1998; **171**: 1203-6.
25. Hann LE, Bach AM, Cramer LD, Siegel D, Yoo HH, Garcia R. Hepatic sonography: comparison of tissue harmonic and standard sonography techniques. *AJR Am J Roentgenol.* 1999; **173(1)**: 201-6.