

# DIAGNOSTIC ACCURACY OF HRCT IN EVALUATION OF PULMONARY TUBERCULOSIS

Mazhar Shafiq,<sup>1</sup> Asha Kumari,<sup>2</sup> Tariq Mehmood,<sup>2</sup> Sadaf Saleem Uppal<sup>2</sup>

<sup>1</sup> Department of Radiology, CMH Kharian Cantt., Pakistan.

<sup>2</sup> Department of Radiology, Jinnah Postgraduate Medical Centre (JPMC), Karachi, Pakistan.

PJR January - March 2019; 29(1): 01-07

## ABSTRACT

**OBJECTIVE:** To determine the diagnostic accuracy of HRCT (higher resolution CT scan) in evaluation of active pulmonary tuberculosis taking sputum AFB as gold standard. **SUBJECT AND METHODS:** Patients of either gender with low grade fever, productive cough for more than 3 months and history of weight loss were included in our study. CT scan with contrast was performed on Toshiba Aquilion with 120 KV and 250 mAs, with a high-spatial-frequency reconstruction algorithm, Slice thickness (1mm), window length - 550 & window width 1600 and patient positioned (supine and/or prone). Diagnostic accuracy of HRCT in evaluation of pulmonary tuberculosis was determined taking sputum AFB as gold standard. **RESULTS:** Mean age of the patients in our study was  $33.74 \pm 10.69$  years. Seventy three (77.7%) patients were of <40 years of age, 92 (97.9%) had productive cough while weight loss was found in 51(54.3%) patients. Sensitivity and specificity of HRCT taking AFB smear as a gold standard was found to be 87.34% and 93.33% respectively. **CONCLUSION:** The diagnostic accuracy of HRCT in evaluation of active pulmonary tuberculosis was found to be high.

**Key Words:** Pulmonary tuberculosis, AFB sputum, HRCT

## Introduction

Worldwide, 1.7 million people die of tuberculosis each year,<sup>1</sup> with nearly  $9 \times 10^6$  new cases of active tuberculosis (TB) are diagnosed, rising at an alarming rate of one percent per annum.<sup>2</sup> Majority i.e. 95% of tuberculosis cases and 98% of deaths due to tuberculosis occur in poor countries of Asia, Africa and South America.<sup>3</sup> Among these regions, 44% of Southeast Asian population is tuberculosis infected.<sup>3</sup> Microbiological detection of Acid Fast Bacillus (AFB) remains the gold standard for diagnosis of active tuberculosis; the sensitivity of sputum smear for AFB is 46-74%, and that of the sputum culture is 2-95% with active pulmonary disease.<sup>4</sup> The national data documents a yield of 10-22% for smear positivity in active pulmonary tuberculosis in adults.<sup>5-6</sup>

Chest radiography remains the main imaging tech-

nique in the evaluation of pulmonary TB. It is unsurpassed in the amount of information it yields in relation to its cost, radiation dose, availability, and ease of performance. However, plain chest radiograph-based diagnosis is correct in only 34% and 59% cases of primary pulmonary TB and post primary pulmonary TB respectively.<sup>7</sup> In one study, the sensitivity, specificity, positive predictive value, negative predictive value and diagnostic accuracy of HRCT in detecting disease activity were 88%, 88%, 92%, 83% and 88%, respectively.<sup>8</sup>

More so, HRCT is more sensitive in detection of miliary nodules,<sup>9</sup> to correlate underlying pathomorphological processes,<sup>10</sup> mode of spread of the disease and sequential morphological changes after anti-tuberculosis chemotherapy.<sup>11</sup> Though the chest radio-

**Correspondence** : Dr. Mazhar Shafiq

Department of Radiology,

CMH Kharian Cantt.,

Pakistan.

Email: mazhardr@hotmail.com

Submitted 6 January 2019, Accepted 11 February 2019

graphy can demonstrate cavitation in 40-87% of patients, HRCT chest has proved to be more accurate in detection of cavitation, particularly in cases complicated by extensive fibrosis and architectural distortion.<sup>7,12,13</sup>

Although diagnostic accuracy of HRCT findings of pulmonary TB have been described in varied international studies, a similar data in the local patients is non-existent. By identification diagnostic accuracy of HRCT, in appropriate clinical settings with atypical or seemingly inactive X-ray chest features and smear negative PTB; the clinician can reach the presumptive diagnosis of active tuberculosis and start empirical therapy.

## Material and Methods

It's a descriptive cross-sectional study conducted at Radiology department, Jinnah Post Graduate Medical Center, Karachi. The study was duly approved by institutional review board. The duration of study was six months. On the basis of expected values (sensitivity 80.0%,<sup>8</sup> specificity 80%,<sup>8</sup> prevalence 44%,<sup>3</sup> desired precision 10% and confidence level as 95%) the estimated sample size came out to be 94 patients. Sampling technique is non-probability consecutive sampling. Inclusion criteria included patients referred by the physician of any age and either sex having the following symptoms, fever: low grade (100° to 100.5° F), cough: productive for 3 months and history of weight loss ( $\geq 10\%$  of body weight). While exclusion criteria included pregnancy, known neoplastic lesion and already diagnosed case of tuberculosis.

Sequential referred patients meeting the inclusion criteria were selected after taking informed consent. Approval from ethical committee was taken prior to conduction of study. Brief history was taken for symptoms as mentioned in the inclusion criteria and their duration. After taking consent for procedure, CT scan with contrast was performed on Toshiba Aquilion with 120KV and 250mAs, with following protocols, a. high-spatial-frequency reconstruction algorithm, such as bone algorithm. b. Slice thickness (1mm). c. Window length -550 & window width 1600. d. patient positioning (supine and/or prone).

Interpretation of CT scan was done by senior radiologist on CT workstation having post fellowship

experience of greater than 5 years. History of symptoms and their duration and findings of the HRCT scan of each patient were recorded in the proforma. The patient sputum for AFB findings was collected and noted in proforma.

## Results

A database was developed on statistical package of social science (SPSS Version 11). The age of patient and duration of symptoms were presented by mean  $\pm$  S.D. Frequency and percentage was calculated for gender, history of fever, cough, and weight loss. Diagnostic accuracy of HRCT in evaluation of pulmonary tuberculosis was determined by comparing with the gold standard sputum for AFB. Stratification was done with regard to age, gender and duration of symptoms to see the effect of these on outcomes.

Ninety four patients meeting the inclusion criteria were recruited in our study. Mean age of the patients in our study was 33.74 years with the standard deviation of  $\pm 10.69$  years. The minimum age was 22 years, while maximum age of 62 years was noticed as shown in (Tab. 1). Mean duration of symptoms of pulmonary tuberculosis was 3.7 months with the standard deviation of  $\pm 0.99$  months. Minimum duration of symptoms was 3 months, while maximum duration of symptoms was 6 months noticed in our study. (Tab. 1).

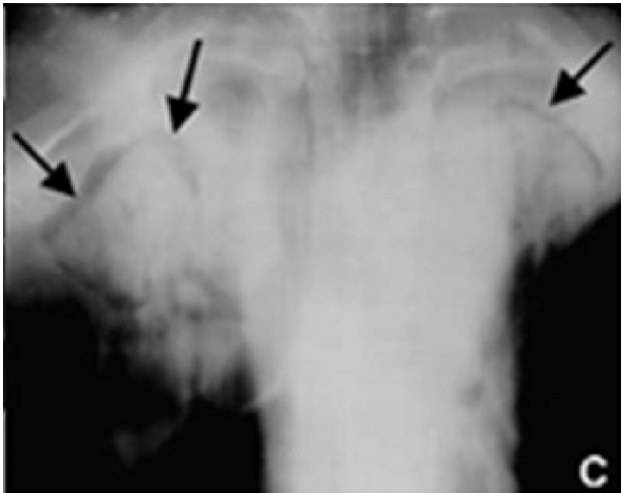
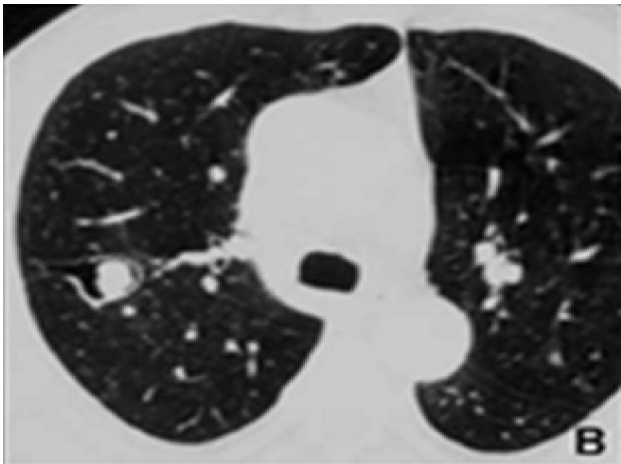
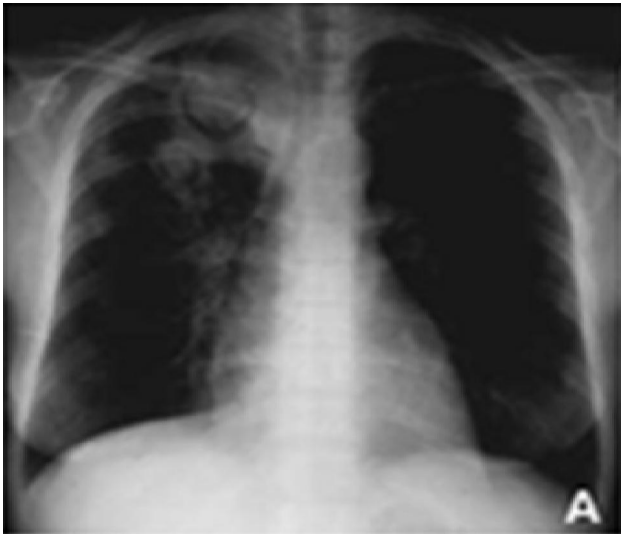	Mean	S.D	Minimum	Maximum
Age of the Patients (in years)	33.74	$\pm 10.69$	22	62
Duration of Symptoms (in months)	3.70	$\pm 0.99$	3	6

**Table 1:** Age of the patients and age of the patients and duration on symptoms

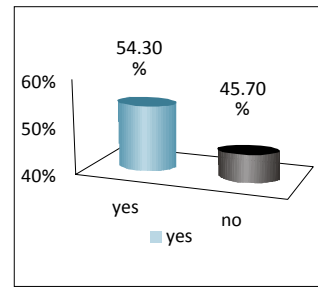
Age distribution shows that, 73 (77.7%) were of <40 years of age, while gender distribution shows that, 78 (83%) patients were male.

As far as symptoms are concerned, low grade fever was found in 75 (79.8%) patients, cough 92 (97.9%), while weight loss was found in 51 (54.3%) patients. (Fig. 1) (Graph 1).

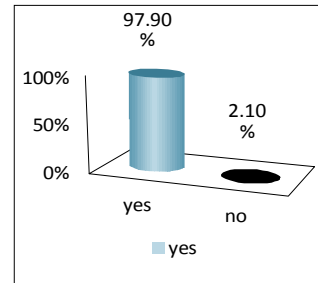
AFB smear positive was found in 79 (84%) patients; while HRCT was positive in 70 (74.5%) cases. (Fig. 2) (Graph 2).



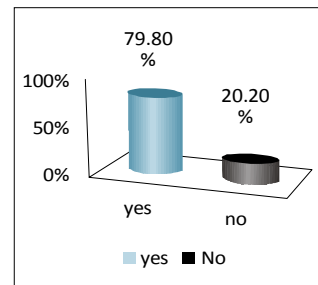
**Figure 1:** Aspergilloma: **A)** Chest film shows two cavities, partially occupied by fungus balls, in the right upper lobe developed within an area of consolidation, **B)** HRCT demonstrates a thin walled cavity in the right upper lobe colonized by an aspergilloma and **C)** on conventional tomography intracavity nodular opacities are present in both upper lobes, separated from the cavity wall by a crescent of air (arrow).



**A:** Frequency of weight loss

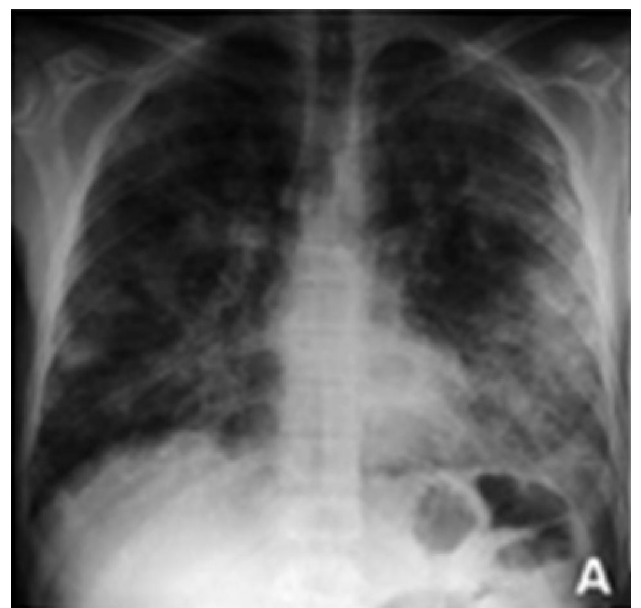

**B:** Frequency of cough



**C:** Frequency of fever

**Graph 1:** Diagnostic accuracy of HRCT in evaluation of pulmonary tuberculosis



**Figure 2A:** Chest Film

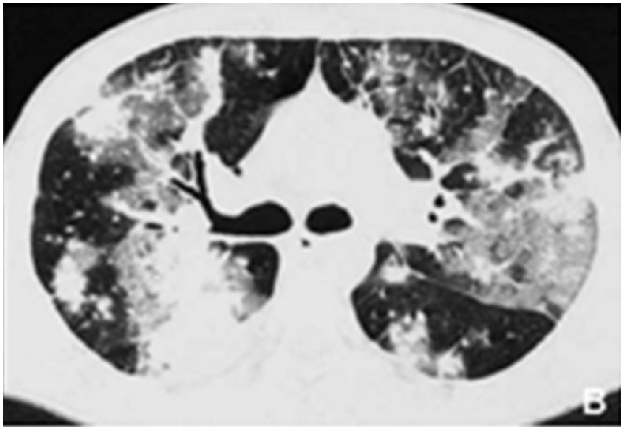
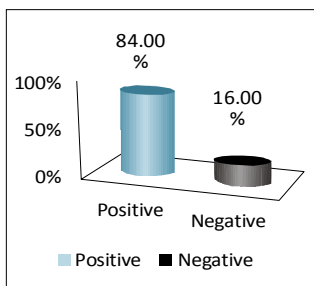
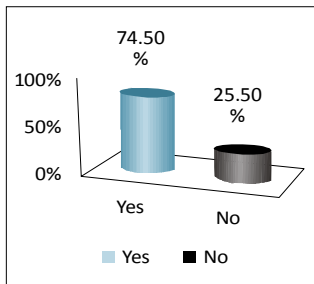


Figure 2b: HRCT



Graph 2A: Sputum for AFB findings



Graph 2B: HRCT findings

Overall diagnostic accuracy of HRCT is shown in (Tab. 2). Sensitivity and specificity was found to be 87.34% and 93.33% respectively. Positive predictive value and negative predictive value was found to be as 98.57% and 58.33% respectively.

HRCT	AFB		Total
	Positive	Negative	
Positive	69	1	70
Negative	10	14	24
Total	79	15	94

Sensitivity = 87.34%  
 Specificity = 93.33%  
 Positive predictive value = 98.57%  
 Negative predictive value = 58.33%

Table 2: Overall diagnostic accuracy of HRCT

Diagnostic Accuracy of HRCT in < 40 years of age patients as shown in (Tab. 3), had 97.10% and 100% sensitivity and specificity respectively, while in ≥40 years, sensitivity and specificity was 25% and 92.3% respectively. (Tab. 3)

Diagnostic Accuracy of HRCT in male gender had 86.36% and 91.6% sensitivity and specificity respectively, while in females, sensitivity and specificity was 92.3% and 100% respectively. (Tab. 4)

Diagnostic Accuracy of HRCT in duration of symptoms ≤3 months had 90.69% and 93.33% sensitivity and specificity respectively, while in duration of symptoms >3 months, sensitivity and specificity was 83% and 100% respectively. (Tab. 5)

HRCT	Age Group <40 years			Age Group ≥40 years		
	AFB Positive	AFB Negative	Total	AFB Positive	AFB Negative	Total
Positive	67	0	67	2	1	3
Negative	2	4	6	6	12	18
Total	69	4	73	8	13	21

Sensitivity = 97.10%      Sensitivity = 25%  
 Specificity = 100%      Specificity = 92.30%  
 Positive predictive value = 100%      Positive predictive value = 66.66%  
 Negative predictive value = 66.66%      Negative predictive value = 66.66%

Table 3: Age groups & diagnostic accuracy of HRCT

HRCT	Male			Female		
	AFB Positive	AFB Negative	Total	AFB Positive	AFB Negative	Total
Positive	57	1	58	12	0	12
Negative	9	11	20	1	3	4
Total	66	12	78	13	3	16

Sensitivity = 86.36%      Sensitivity = 92.30%  
 Specificity = 99.16%      Specificity = 100%  
 Positive predictive value = 98.27%      Positive predictive value = 100%  
 Negative predictive value = 55%      Negative predictive value = 75%

Table 4: Gender & diagnostic accuracy of HRCT

HRCT	Duration of Symptoms ≤3			Duration of Symptoms >3		
	AFB Positive	AFB Negative	Total	AFB Positive	AFB Negative	Total
Positive	39	1	40	30	0	30
Negative	4	14	18	6	0	6
Total	43	15	58	36	0	42

Sensitivity = 90.69%      Sensitivity = 83.33%  
 Specificity = 93.33%      Specificity = 0%  
 Positive predictive value = 97.5%      Positive predictive value = 100%  
 Negative predictive value = 77.77%      Negative predictive value = 0%

Table 5: Duration of symptoms & diagnostic accuracy of HRCT

## Discussion

The age of patient and duration of symptoms were presented by mean  $\pm$  S.D. Frequency and percentage was calculated for gender, history of fever, cough, and weight loss. Diagnostic accuracy of HRCT in evaluation of pulmonary tuberculosis was determined by comparing with the gold standard sputum for AFB. Stratification was done with regard to age, gender and duration of symptoms to see the effect of these on outcomes. Million people die of tuberculosis each year,<sup>1</sup> and nearly  $9 \times 10^6$  new cases of active tuberculosis (TB) are diagnosed, rising at an alarming rate of one percent per annum.<sup>2</sup>

Several previous studies evaluated clinical characteristics and scoring systems for the diagnosis of sputum smear-negative PTB.<sup>14-16</sup> Samb et al.<sup>14</sup> reported independent predictors of active PTB including a chronic cough lasting longer than 3 weeks, chest pains longer than 15 days, absence of sputum, and absence of dyspnea, and Lee et al.<sup>16</sup> reported that the lack of sputum was a positive predictor of active PTB. But even in these studies, the specificity of the clinical predictors or scoring system was low, and the PPV was reported at a mere 50%.

Despite being less infectious than sputum smear-positive PTB, smear-negative PTB serves as an important cause of transmission in communities by delaying diagnosis and precluding initiation of treatment and often leads to complications of irreversible lung damage in infected individuals.<sup>17</sup> Matsuoka et al.<sup>18</sup> stated that CT findings in sputum smear-negative patients differed from those in smear-positive patients and suggested that CT findings are not helpful in judging sputum smear-negative TB suspects.

In previous studies, HRCT had a sensitivity of 60-80% and a specificity of 50-70%.<sup>16,19,20</sup> Our results indicate that HRCT has a similar sensitivity of 87.34% and specificity of 93.33%. In one study, the sensitivity, specificity, positive predictive value, negative predictive value and diagnostic accuracy of HRCT in detecting disease activity were 88%, 88%, 92%, 83% and 88%, respectively.<sup>8</sup>

More so, HRCT is more sensitive in detection of miliary nodules;<sup>9</sup> to correlate underlying pathomorphological processes,<sup>10</sup> mode of spread of the disease and sequential morphological changes after antituberculosis chemotherapy.<sup>11</sup> Though the chest radiogra-

phy can demonstrate cavitation in 40-87% of patients, HRCT chest has proved to be more accurate in detection of cavitation, particularly in cases complicated by extensive fibrosis and architectural distortion.<sup>7,12,13</sup>

The high cost and concerns about the radiation exposure of HRCT limit the usefulness of this test. One previous study investigating the cost-effectiveness of HRCT in the diagnosis of PTB<sup>20</sup> reported that HRCT play significant roles in the moderate or high PTB probability setting compared with the low PTB probability setting. Considering the high specificity of our study, HRCT would be useful in a high TB burden country.

One recurring dilemma in the practice of respiratory medicine in Pakistan is the differentiation of tuberculosis from other causes of lung diseases. TB is a great mimicker and has a myriad of clinical and radiological presentations. The transbronchial dissemination of TB with lymphatic and perilymphatic involvement of the lung interstitium is sometimes difficult to distinguish from other causes of interstitial abnormalities as demonstrated on plain chest X-rays. HRCT plays a vital role in differentiating granulomatous processes from other DPLDs.<sup>21,22</sup> Although the features of TB such as centrilobular nodularity and 'tree in bud' appearances are not pathognomonic, they are distinctive enough to strongly suggest TB.<sup>23,24</sup>

## Conclusion


The diagnostic accuracy of HRCT in evaluation of active pulmonary tuberculosis was found to be high.

**Conflict of Interest:** None

## References

1. Global tuberculosis control: surveillance, planning, financing. Geneva: WHO, 2006.
2. World Health Organisation. Global tuberculosis control: surveillance, planning, financing. Geneva: WHO, 2005.

3. Akhtar S, White F, Hasan R, Rozi S, Younus M, Ahmed S, et al. Hyperendemic pulmonary tuberculosis in peri-urban areas of Karachi, Pakistan. *BMC Public Health* 2007; **7**: 70.
4. Raniga S, Parikh N, Arora A, Vaghani M, Vora PA, Vaidya V. Is HRCT reliable in determining disease activity in pulmonary tuberculosis? *Indian J Radiol Imaging*. 2006; **16**: 221-8.
5. Khan MB, Mashood AA, Qureshi WA, Ibrar K. Tuberculosis disease pattern and the sputum microscopy yield. *Pak J Chest Med*. 2005; **11**: 11-9.
6. Iqbal R, Shabbir I, Waseem T. Screening of AFB in sputum by concentration or direct smear method. *Pak J Med Res*. 2000; **39**: 35-6.
7. Woodring JH, Vandiviere HM, Fried AM, Dillon ML, Williams TD, Melvin IG. The radiographic features of pulmonary tuberculosis update. *AJR*. 1986; **146**: 497-506.
8. Tozkoparan E, Deniz O, Ciftci F, Bozkanat E, Bicak M, Mutlu H, et al. The roles of HRCT and clinical parameters in assessing activity of suspected smear negative pulmonary tuberculosis. *Arch Med Res*. 2005; **36**: 166-70.
9. Oh YW, Kim YH, Lee NJ, Kim JH, Chung KB, Suh WH, et al. High-resolution CT appearance of miliary tuberculosis. *J Comput Assist Tomogr*. 1994; **18**: 862-6.
10. Goo JM, Im JG. CT of tuberculosis and non-tuberculous mycobacterial infections. *Radiol Clin North Am*. 2002; **40**: 73-87.
11. Im JG, Itoh H, Lee KS, Han Mc. CT of pulmonary tuberculosis. *Semin Ultrasound CT MR*. 1995; **16**: 420-34.
12. Christensen EE, Dietz GW, Ahn CH, Chapman JS, Murry RC, Anderson J, et al. Initial roentgenographic manifestations of pulmonary mycobacterium tuberculosis, *M. kansasii* and *M. intracellulare* infections. *Chest*. 1981; **80**: 132-6.
13. Kuhlman JE, Deutsch JH, Fishman EK, Siegelman SS. CT features of thoracic mycobacterial disease. *Radiographics*. 1990; **10**: 413-31.
14. Giron J, Couture A, Bousquet C, et al. Imagerie de la tuberculose pulmonaire en 1991. *Encycl Méd Chir, Radiodiagnostic-Coeur-Poumon-Larynx*, 32390 A 10, 1991. p. 1-12.
15. Palmer PES. *The imaging of tuberculosis*. Berlin: Springer-Verlag; 2002. p. 5-49.
16. Samb B, Henzel D, Daley CL, Mugusi F, Niyongabo T, MlikaCabanne N, Kamanfu G, Aubry P, Mbagala I, Larouze B, Murray JF: Methods for diagnosing tuberculosis among inpatients in Eastern Africa whose sputum smears are negative. *Int J Tuberc Lung Dis* 1997; **1**: 25-30.
17. Tessema TA, Bjune G, Assefa G, Bjorvat B: An evaluation of the diagnostic value of clinical and radiological manifestations in patients attending the addis ababa tuberculosis centre. *Scand J Infect Dis* 2001; **33**: 355-61.
18. Lee HM, Shin JW, Kim JY, Park IW, Choi BW, Choi JC, Seo JS, Kim CW: HRCT and whole-blood interferon-gamma assay for the rapid diagnosis of smear-negative pulmonary tuberculosis. *Respiration* 2010, **79**: 454-60.
19. Foulds J, O'Brien R: New tools for the diagnosis of tuberculosis: the perspective of developing countries. *Int J Tuberc Lung Dis* 1998; **2**: 778-83.
20. Matsuoka S, Uchiyama K, Shima H, Suzuki K, Shimura A, Sasaki Y, Yamagishi F: Relationship between CT findings of pulmonary tuberculosis and the number of acidfast bacilli on sputum smears. *Clin Imaging* 2004, **28**: 119-23.
21. Lai FM, Liam CK, Paramsothy M, George J: The role of 67gallium scintigraphy and high resolution computed tomography as predictors of disease activity in sputum smear-negative pulmonary tuberculosis. *Int J Tuberc Lung Dis* 1997, **1**: 563-69.

- 
- 
22. Lim TK, Cherian J, Poh KL, Leong TY: The rapid diagnosis of smear-negative pulmonary tuberculosis: a cost-effectiveness analysis. *Respirology* 2000, **5**: 403-9.
  23. Webb WR, Muller NL, Naidich DP. High-Resolution CT of the lung. 3rd ed. Philadelphia: Lippincott Williams & Wilkins; 2001.
  24. Gotway MB, Reddy GP, Webb WR, Elicker BM, Leung JW. High-resolution CT of the lung: patterns of disease and differential diagnosis. *Radiol Clin N Am* 2005; **43**: 513-42.