

# THE SHARP "S" SHAPED INTERNAL CAROTID ARTERY: A RARE ANATOMICAL VARIATION

Abdul Wahab Faiz Alahmari

Department of Radiology, College of Medicine, King Saud University, Saudi Arabia.

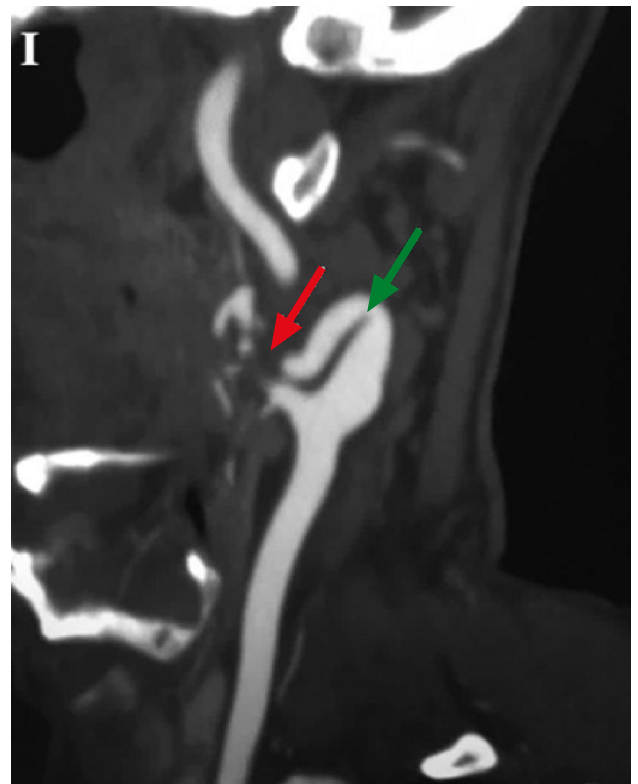
PJR January - March 2019; 29(1): 57-59

## ABSTRACT

Rare anatomical variations along with medical imaging artifacts can result in a wrong diagnosis. This case report will present an incidence of a sharp "S" shaped internal carotid artery in combination with a motion artifact of the carotid artery pulsation, which was initially thought to be the result of carotid dissection.

## Case Report

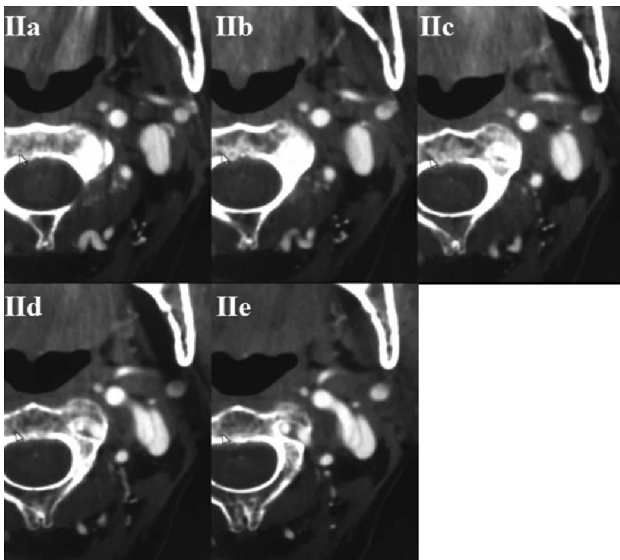
A 35-year-old male patient came to the emergency room at Ballasmer General Hospital complaining from a migraine, headache, dizziness, and neck pain. The patient had no previous history of chronic illness. The vital signs were as follows: a blood pressure reading of 125/93, with a pulse rate of 87 beats per minute, a respiratory rate of 16 breaths per minute, a temperature of 37.2 °C, and an evaluation of 15/15 on the Conscious Glasgow Scale (GCS). The emergency physician referred the patient to a neurologist. The neurologist requested that a Computed Tomography (CT) scan be conducted for the head and neck with contrast. The CT scan displayed a twisted and enlarged left internal carotid artery. This twisted internal carotid artery was initially thought to be the result of dissection after images of it were interpreted by the neurologist (Fig. 1). However, the radiologist who was on duty at the time ruled out the possibility of dissection, stating that it was more likely to be a tortuous internal carotid artery which is normal anatomical variation (Fig. 2). This rare anatomical variation was found in the left internal carotid artery, which appeared as a sharp "S" shaped internal carotid artery (Fig. 3). Furthermore, the pulsation artifact of the internal carotid artery was what contributed to making the wrong diagnosis. This anatomical variation was evident on one side only. Due



**Figure 1:** (The 35-year-old male). The coronal CT for the neck shows the tortuous sharp "S" shaped internal carotid artery (as indicated by the green arrow). The pulsation artifact of the internal carotid artery is what caused the discontinuation of the carotid artery and motion artifact in this case (as indicated by the red arrow).

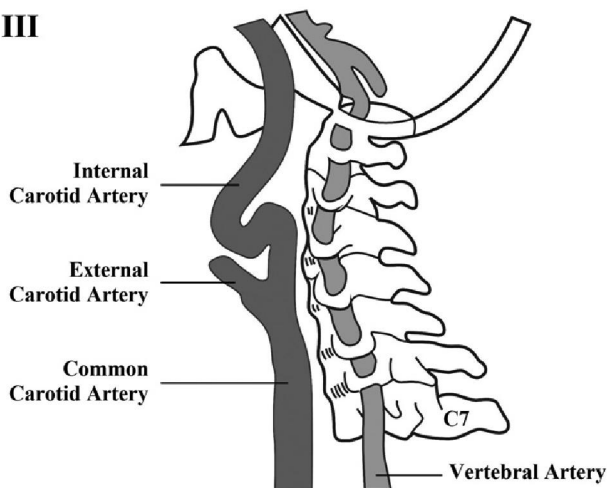
**Correspondence** : Dr. Abdul Wahab Faiz Alahmari  
 Department of Radiology,  
 College of Medicine, King Saud University,  
 Saudi Arabia.  
 Email: afaa99@hotmail.co.uk

Submitted 9 December 2018, Accepted 30 January 2019



**Figure 2:** (The 35-year-old male). The axial CT images for the neck demonstrate the continuation of the internal carotid artery and rule out dissection. (See segment IIa) for the carotid bifurcation level, (see segments IIb and IIc) for the carotid sinus level, and (see segments IId and IIe) for the carotid twisted loop level.

### III



**Figure 3:** Provides an illustration of the twisted "S" shaped internal carotid artery.

to the anatomical variation of the carotid artery and motion artifact, the neurologist who examined this case thought mistakenly that this was abnormality.

## Discussion

An internal carotid artery has seven segments, four of which are intracranial. These are, namely, the cavernous, clinoid, ophthalmic, and communicating

segments. The rest of the segments, which are located in the neck are known as the cervical, petrous, and lacerum segments. The anatomical variation of the internal carotid artery, at the levels of C3-C5, is common in 48.1% of the anatomical variation cases in carotid artery.<sup>1</sup> The bilateral twisted internal carotid artery in ischemic stroke patients can contribute to forming a carotid dissection.<sup>2</sup> The catheterization in a twisted internal carotid artery can be difficult to perform, and it requires more time for the catheter to pass the curves of such an entity.<sup>3</sup> There are three degrees of curving, which are, namely, mild curving known as kinking, moderate curving known as tortuous curving, and severe curving known as coiled curving.<sup>4,5</sup> Moreover, this case was deemed to be high-risk, with vascular implications since it was classified as having severe coiling, according to the modified criteria of Weibel-Fields and Metz.<sup>4,5</sup>

## Teaching Points

Coiled internal carotid arteries can be found combined with motion artifacts as a result of carotid pulsations. A twisted internal carotid artery combined with the occurrence of an ischemic stroke will increase the risk factor of carotid dissection. Additionally, the catheterizing of a coiled internal carotid artery can prove to be difficult.

**Conflict of Interest:** None

## References

1. Bouthillier A, Van Loveren HR, Keller JT. Segments of the internal carotid artery: a new classification. *Neurosurgery*. 1996; **38(3)**: 425-33.
2. Haussen DC, Jadhav A, Rebello LC, Belagaje S, Anderson A, Jovin T, et al. Internal Carotid Artery S-Shaped Curve as a Marker of Fibromuscular Dysplasia in Dissection-Related Acute Ischemic Stroke. *Interventional neurology*. 2016; **5(3-4)**: 185-92.
3. Lin LM, Colby GP, Jiang B, Uwandu C, Huang J, Tamargo RJ, et al. Classification of cavernous

---

internal carotid artery tortuosity: a predictor of procedural complexity in Pipeline embolization. *Journal of neurointerventional surgery*. 2015; **7(9)**: 628-33.

4. Togay-Isikay C, Kim J, Betterman K, Andrews C, Meads D, Tesh P, et al. Carotid artery tortuosity, kinking, coiling: stroke risk factor, marker, or curiosity?. *Acta neurologica belgica*. 2005; **105(2)**: 68.
5. Weibel J, Fields WS. Tortuosity, coiling, and kinking of the internal carotid artery I. Etiology and radiographic anatomy. *Neurology*. 1965; **15(1)**: 7-7.